CODEN [USA]: IAJPBB ISSN : 2349-7750

INDO AMERICAN JOURNAL OF
PHARMACEUTICAL SCIENCES
SJIF Impact Factor: 7.187
http://doi.org/10.5281/zenodo.4040419

Available online at: http://www.iajps.com *Review Article*

SEVERE LACTIC ACIDOSIS AND HYPOGLYCEMIA IN A PATIENT WITH B-CELL LYMPHOMA A CASE REPORT AND LITERATURE REVIEW

[1]Eyad Muwaffaq Alsaqqa, [2]Ibrahim Ajwa, [3]DR. Roaid Khan, [4]Dr.Aftab Ahmed

[1]Internal Medicine Resident, King Salman Armed Forced Hospital, Tabuk, Saudi Arabia

[2]Internal medicine resident, King Salman Armed Forced Hospital, Tabuk, Saudi Arabia

[3]consultant of endocrinology, King Salman Armed Forced Hospital, Tabuk, Saudi Arabia

[4]Consultant of internal Medicine, King Salman Armed Forced Hospital, Tabuk, Saudi Arabia

Abstract:

Diffuse large B-cell lymphoma (DLBCL) considered most common form of non- Hodgkin lymphoma, and it is considered as an aggressive (fast growing) that affect B- lymphocyte. The occurrence of DLBCL generally increases with age, and most patients are over the age of 60 at diagnosis. It account for about 22 percent of newly diagnosed cases of B-cell NHL in the United States. More than 18,000 people are diagnosed with DLBCL each year. [R]

We report a case of 41 year old female known case of diabetes, patient reported DVT distal unprovoked 6 months ago treated by Rivaroxaban for 3 months. Take care of two children. Presented to surgery outpatient clinic with complain of left breast mass, during course of hospitalization, biopsies were taken from breast and liver showed; non-Hodgkin's lymphoma high grade diffuse large cell, germinal center type. Patient was complicated by sever lactic acidosis and hypoglycemia which found to be resistant to traditional way of treatments. The pathogenesis of malignancy induced lactic acidosis and hypoglycemia is not well understood. Prompt diagnosis and treatment of underlying lymphoma or leukemia remain the only way to achieve complete resolution of lactic acidosis and hypoglycemia for these patients.

Corresponding author:

Eyad Muwaffaq Alsaqqa,
Internal Medicine Resident,
King Salman Armed Forced Hospital, Tabuk,
Saudi Arabia

QR code

Please cite this article in press Eyad Muwaffaq Alsaqqa et al, Severe Lactic Acidosis And Hypoglycemia In A Patient With B-Cell Lymphoma A Case Report And Literature Review., Indo Am. J. P. Sci, 2020; 07(09).

INTRODUCTION:

Diffuse large B-cell lymphoma (DLBCL) considered most common form of non-Hodgkin lymphoma, and it is considered as an aggressive (fast growing) that affect B-lymphocyte. The occurrence of DLBCL generally increases with age, and most patients are over the age of 60 at diagnosis. It accounts for about 22 percent of newly diagnosed cases of B-cell NHL in the United States. More than 18,000 people are diagnosed with DLBCL each year. *[R]*

CASE REPORT:

41-year-old female have history of insulin non-dependent diabetes mellitus, with pervious history of deep venous thrombosis distal non provoked treated by three months of direct oral anticoagulation (named Rivaroxaban). Presented to surgical clinic by low grade fever more at night, loss of appetite, shortness of breath and left breast mass began 3months back and progress since then.

Vitally stable, no detectable lymph node enlargement, thyroid gland not palpable, Abdomen soft lax with splenic enlargement 4 fingers width, and liver enlargement 3 fingers width below costal margins, left tender-less breast mass with redness of skin can be palpated on upper lateral and areolar regions with no discharge from the nipple, on day of admission arterial blood gases taken which reveal sever lactic acidosis (PH.7.20. lactate .16.3mmol/L) resistant to sodium bicarbonate and dialysis, hypoglycemia (45-70 mg/dl) resistance to glucose infusion. Serum insulin, pro-insulin, c-peptide levels were normal, thyroid and cortisol level were normal, CT angiography was normal. (Figure1) second day of hospital admission left breast mass biopsy was taken ultrasound guided. (Figure 2) . The result of breast tissue come as inconclusive, TRU-CUT biopsy CT guided of liver decided and done on fourth day of admission (Figure 3). Histopathology report of the liver biopsy was reported as (Lymphomatous involvement by non-Hodgkin's lymphoma high grade diffuse large cell, germinal center type). After which chemotherapy by *R-CHOP (rituximab, cyclophosphamide, doxorubicin, vincristine, and prednisolone)* were decided by oncology team. After first dose clinical and laboratory improvement was obvious, lactic acidosis and hypoglycemia began to improve , dialysis not on need any more and glucose infusion stopped.

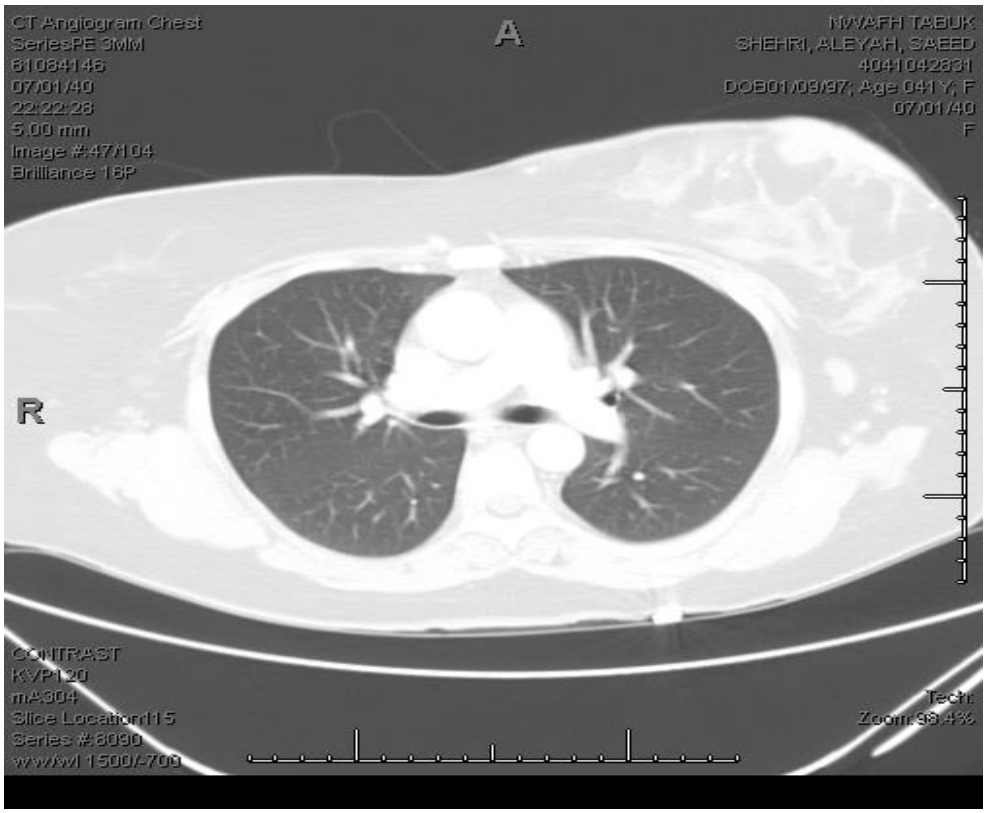

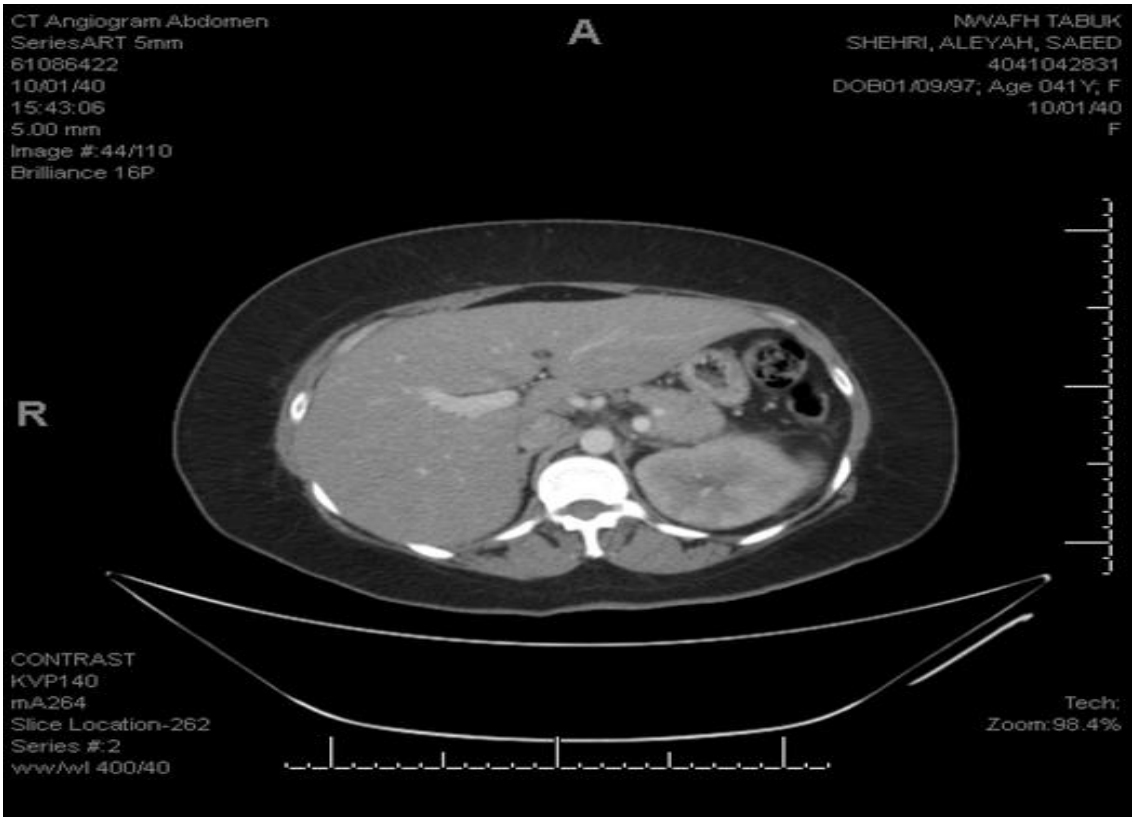

DISCUSSION:

Lactic acidosis is defined as persistent increase in

blood lactate level (usually more than 5mmol) in association with metabolic acidosis. Lactic acid is a usual endpoint product of pyruvate in condition of anaerobic energy production so accumulation will happen in condition of increase production or decrease excretion. where it divided to L-lactate produced by human metabolism and D-lactate produced by bacteria like in case of short bowel syndrome, L-lactate can divide to type A caused by clinical evidence of poor tissue perfusion or oxygenation where type B for causes where no clinical evidence of poor tissue perfusion. Hypoglycemia defined as blood sugar less than 3.9 mmol /dl, there are several reasons why this can happen; the most common is a side effect of drugs used to treat diabetes.

Diffuse Large B cell lymphoma (DLBCL) considered as the commonest form of non-Hodgkin lymphoma (NHL) in the United States and worldwide, accounting for about 22 percent of newly diagnosed cases of B-cell NHL in the United States. More than 18,000 people are diagnosed with DLBCL each year. (DLBCL) represent 30-40% of non-Hodgkin lymphoma subtypes first presentation usually include a painless swelling on the neck, axilla, or groin caused by enlarged lymph node, sometime can originate from other part of the body which known as extra nodal. There are rare types like Primary mediastinal large B-cell lymphoma: accounts for 2-4% of all non-Hodgkin lymphomas and usually affect people between 25-40 years old , T-cell/histiocyte-rich large B-cell lymphoma: more common in men aged over 50 years but can affect people of any age less than 10% of (NHL) have this type , Intravascular large B-cell lymphoma: extremely rare form of lymphoma. Occurs in adults with the average age at diagnosis being 65 years. *[m]*

As by Sillos et al they reported lactic acidosis in 28 cases of lymphoma and 25 cases of leukemia. While hypoglycemia present in 20 cases over 53 cases reviewed by them. the author notice that the acidosis improved only if the disease responded to chemotherapy. [6]

And lactic acidosis with lymphoma and leukemia were reported by Friedenberg et al [7] and Ruiz et al [8].

The cause of lactic acidosis and hypoglycemia in lymphoma and leukemia not well understood , possible causes could be due to liver metastasis and dysfunction as liver use lactic acid in the process of gluconeogenesis , however lactic acidosis can happen in absence of liver involvement where Sillos et al reported lactic acidosis in hematological malignancies not involving liver (19%)[6]. Another mechanism possibly cause lactic acidosis is increased glycolysis activity with subsequent over generation of lactic acid in cancer cell [9], [10].

ANOTHER HYPOTHESIS can explain both lactic acidosis and hypoglycemia : What observed in hematological malignancy cells tend to uptake glucose by high amount and instead of utilize it by the usual way of oxidative phosphorylation as normal cells they do what called aerobic glycolysis (Warburg Effect) so tumor cells use glucose and produce lactic acid aiming for energy production but by less effective pathway than the usual oxidative phosphorylation even with enough oxygen and fully functioning mitochondria . [11], [12].another hypothesis can explain it formation of levated levels of Substance Immunologically Cross-Reactive with Insulin (SICRI). Although their observations did not demonstrate that SICRI facilitates glucose uptake by tissues, they speculated that these substances play a role in positive feedback of the endocrine self-control mechanism of tumor growth [13]. Another hypothesis postulated that tumor cell secrete antibody imitate insulin and can activate insulin receptor enhancing cell uptake of glucose [14].

CONCLUSION:

we presented a case report of Diffuse large B cell lymphoma in 41 year old lady presented to clinic with unique presentation of lactic acidosis and hypoglycemia associated by extranodal swelling with no lymph node involvement progressed rapidly over few weeks, many theories were postulated for explanation of lactic acidosis and hypoglycemia which initially treated by intravenous infusion of glucose , sodium bicarbonate and hemodialysis but was resistant and improvement which is the main purpose of our case report observed only after tumor respond to chemotherapy confirmed in our case by bone marrow biopsy after first dose of chemotherapy reported as (Hypo-plastic bone marrow) .

REFERENCES:

1. Cohen R, Woods H. *Clinical and Biochemical Aspects of Lactic Acidosis*. Blackwell Scientific Publications; 1976.
2. Stacpoole PW. Lactic acidosis and other mitochondrial disorders. *Metabolism*. 1997 Mar. 46(3):306-21. [Medline].
3. Sia P, Plumb TJ, Fillaus JA. Type B Lactic Acidosis Associated With Multiple Myeloma. Am J Kidney Dis. 2013 Jun 4. [Medline].
4. Mégarbane B, Brivet F, Guérin JM, Baud FJ. [Lactic acidosis and multi-organ failure secondary to anti-retroviral therapy in HIV-infected patients]. *Presse Med*. 1999 Dec 18-25. 28(40):2257-64. [Medline].

5. "Cori Cycle Archived 2008-04-23 at the Wayback Machine". Retrieved May 3, 2008, from Elmhurst, pp. 1–3.
6. Sillos EM , Shenep JL , Burghen GA , Pui CH , Behm FG , Sandlund JT 2001 Lactic acidosis: a metabolic complication of hematologic malignancies. Case report and review of the literature. Cancer 92:2237–2246
7. Friedenberg AS , Brandoff DE , Schiffman FJ 2007 Type B lactic acidosis as a severe metabolic complication in lymphoma and leukemia: a case series from a single institution and literature review. Medicine (Baltimore)
8. Ruiz JP , Singh AK , Hart P 2011 Type B lactic acidosis secondary to malignancy: case report, review of published cases, insights into pathogenesis, and prospects for therapy. ScientificWorldJournal 11:1316–1324
9. G. Di Comite, L. Dagna, P. M. Piatti, L. D. Monti, F. Tantardini, and L. Praderio, ―Hypoglycaemia and lactic acidosis in a MALT non Hodgkin's lymphoma,‖ *Leukemia and Lymphoma*, vol. 43, no. 6, pp. 1341–1342, 2002.View at: Google Scholar
10. J. J. Glasheen and M. D. Sorensen, ―Burkitt's lymphoma presenting with lactic acidosis and hypoglycemia—a case presentation,‖ *Leukemia and Lymphoma*, vol. 46, no. 2, pp. 281–283, 2005.View at: Publisher Site | Google Scholar
11. Warburg O. The metabolism of carcinoma cells. The Journal of Cancer Research. 1925;9(1):148–163.
12. Warburg O, Posener K, Negelein E. Ueber den stoffwechsel der tumoren. Biochemische Zeitschrift. 1924;152(1):319–344.
13. Pavelić K., Odavić M., Pekić B., Hršak I., Vuk-Pavlović S. Correlation of substance(s) immunologically cross-reactive with insulin, glucose and growth hormone in Hodgkin Lymphoma patients. *Cancer Letters*. 1982;17(1):81–86. doi: 10.1016/0304-3835(82)90112-4. [PubMed] [CrossRef] [Google Scholar
14. Chan J. C. N., Zhu S. Q., Ho S. K. S., Cockram C. S. Hypoglycaemia and Hodgkin's disease. *British Journal of Haematology*. 1990;76(3):434–436. doi: 10.1111/j.1365-2141.1990.tb06381.x. [PubMed] [CrossRef] [Google Scholar]