



CODEN [USA]: IAJPBB

ISSN: 2349-7750

**INDO AMERICAN JOURNAL OF
PHARMACEUTICAL SCIENCES**<http://doi.org/10.5281/zenodo.3883582>Available online at: <http://www.iajps.com>

Research Article

**AN EXPERIMENTAL EVALUATION OF
NEPHROPROTECTIVE POTENTIAL OF ACORUS CALAMUS
EXTRACT IN ALBINO RATS****B. Maheswari Reddy^{1*}, C.K. Dhanapal², B.V.S. Lakshmi¹**¹Department of Pharmacology, Malla Reddy College of Pharmacy, Dhulapally,
Maisammaguda, Secunderabad 500014, Medchal, Telangana, India.²Department of Pharmacy, Annamalai University, Chidambaram, Tamilnadu., India.**Article Received:** April 2020**Accepted:** May 2020**Published:** June 2020**Abstract:**

The aim of this study was to assess the possible protective and curative effects of *Acorus calamus* against Al-induced impairment kidney in albino rat and to explore the mechanism behind this effect. This experimental animal-based study included 36 albino rats divided into six groups. Group-I control, Group-II -AlCl₃-treated (40 mg/kg), Group-III Vitamin E (100 mg/kg b.w, p.o) , Group IV, V, VI received methanolic extract of rhizomes of *Acorus calamus* (MEAC) (100 mg/kg b.w, p.o, 200 mg/kg b.w, p.o, 400 mg/kg b.w, p.o) respectively for a period of 35 days. At the end of the experiment, renal functions as well as the biomarkers of antioxidants activities were assessed in the serum. Kidney were dissected out and histopathologic ally examined. This study showed that administration of AlCl₃ caused a significant increase in the weight of the kidney. It significantly increased serum urea, uric acid, creatinine and BUN levels. AlCl₃ notably inhibited the GPx activity, reduced GSH, GR, CAT levels and increased MDA level in rat kidney. Histopathologically, it induced necrosis and degeneration of glomeruli, and renal tubules.

Key words: Nephroprotective, Aluminium chloride, *Acorus calamus*, methanolic extract.

Corresponding author:**B. Maheswari Reddy,**

Department of Pharmacology,
Malla Reddy College of Pharmacy, Dhulapally,
Maisammaguda, Secunderabad 500014,
Medchal, Telangana, INDIA.

E-Mail: mahi.unaj@gmail.com

QR code



Please cite this article in press B. Maheswari Reddy et al, *An Experimental Evaluation Of Nephroprotective Potential Of Acorus Calamus Extract In Albino Rats.*, Indo Am. J. P. Sci, 2020; 07(06).

INTRODUCTION:

Aluminum (Al) is among the most abundant elements on the earth. Absorption or accumulation of Al in humans occurs via diet as in some food products and additives medication like antacids vaccines and parenteral fluids, adding to cosmetics, inhaled fumes, and particles from occupational exposures [1]. Aluminum gets access to the body via the gastrointestinal and respiratory tracts and accumulates in many tissues, such as kidney, liver, heart, blood, bone and brain [2]. The toxic effect of aluminum has been suggested to be mediated by reactive oxygen species generation resulting in the oxidative deterioration of cellular lipids, proteins and DNA and also induces changes in the activities of tissue antioxidant enzymes [3] altered gene expression and apoptosis [4]. The induced oxidative stress by aluminum and its salts is responsible for hepatotoxicity [5], nephrotoxicity, cardiac toxicity, reproductive toxicity and also neurodegenerative disease and Alzheimer like neurofibrillary tangle formation [6]. Therefore, the external supply of antioxidants is important to suppress caspase activation and for the defense against the deleterious effects of oxidative stress. Although several chelating agents and antagonists are established to reduce the metal toxicity, some of them are burdened with undesirable side effects [7]. Due to the intrinsic limitations and variability of efficacy of heavy metal chelating agents, metal intoxication therapy is looking for the development of new therapeutic agents with different actions especially from phytochemicals [8].

Acorus calamus (AC) commonly known as Bach has been used in the Indian and Chinese system of medicine for hundreds of years to cure disease especially the CNS abnormalities. Ethanolic extract of this plant traditionally used for antidiabetic [9] antiproliferative and immunosuppressive [10], Antidiarrheal [11] and Hypolipidemic [12] activities. It is reportedly useful in clearing speech in children [13] In Ayurvedic medicine, it is used for the treatment of insomnia, melancholia, epilepsy, hysteria, loss of memory, remittent fever and neurosis. Recently, *Acorus calamus* has been reported to possess high antioxidant activity. Reports suggest that the rhizome contains active ingredients possessing insecticidal [14], antifungal [15], antibacterial, and mitogenic activities towards human lymphocytes. An earlier study showed that the essential oil from this plant is β -asarone that possesses anti-carcinogenic, anti-proliferative, and immunosuppressive activity, besides sedative and hypothermic effects. Based on this background, the present study was carried out to investigate the possible Nephroprotective activity of AC against $AlCl_3$ induced intoxication.

MATERIALS AND METHODS:

Materials

All chemicals, used in this study, were of analytical grade. Aluminum chloride ($AlCl_3$) was purchased from Sigma Chemical Company, St. Louis, Missouri, USA. The fresh rhizomes of *Acorus calamus* were collected from the outskirts of Maisammaguda situated in the state of Telangana (India) and the methanol extract was prepared using soxhlet extraction process.

Animals

An ethical approval of this experimental study was obtained from the Institutional Animal Ethical Committee of Malla Reddy College of pharmacy, Hyderabad with Reg. No 1217/PO/Re/S/08/CPCSEA. Thirty six albino rats with average body weight from 150 to 250 g were utilized in this study. They were procured from Teena labs, Plot no 41, SV cooperative industrial estates, Bachupally (V), Quthbullapur. The rats were housed in polypropylene cages and maintained under standard conditions (12h light and dark cycles at $25 \pm 3^\circ C$ and 35-60 % humidity). Standard pelletized feed and tap water were provided *ad-libitum*.

Experimental Design

Rats were randomly divided into six groups (n=6 each). The first group (Group-I) included the control rats which received distilled water, in Group-II $AlCl_3$ treated group- injected with $AlCl_3$ daily at a dose 40 mg/kg b.w/p.o for 5 weeks, in Group-III Vitamin-E treated group-injected with $AlCl_3$ 40 mg/kg b.w/p.o and Vitamin-E 100 mg/kg b.w., in Group-IV $AlCl_3$ + MEAC group- injected with $AlCl_3$ 40 mg/kg b.w and methanolic extract of *Acorus calamus* 100 mg/kg b.w/p.o. daily for 5 weeks, in Group-V: $AlCl_3$ + MEAC group- injected with $AlCl_3$ 40 mg/kg b.w/p.o and methanolic extract of *Acorus calamus* 200 mg/kg b.w/p.o. daily for 5 weeks and in Group-VI: $AlCl_3$ + MEAC group- injected with $AlCl_3$ 40 mg/kg b.w/p.o and methanolic extract of *Acorus calamus* 400 mg/kg b.w/p.o. daily for 5 weeks. At the end of the experiment, rats were fasted overnight. The body weight of the rats was measured. The animals were sacrificed on 35th day by carbon dioxide inhalation through euthanasia chamber & blood was immediately collected by carotid bleeding method. Blood was centrifuged using Remi centrifuge at 4000 rpm for 15 mins & the resultant serum was collected and stored at $-20^\circ C$ till analysis. Rat kidneys were dissected rapidly, a part of these tissues was minced and then homogenized with phosphate buffer using tissue homogenizer. Homogenates were centrifuged at $10,000 \times g$ for 15minutes at $4^\circ C$ and the resultant supernatant was removed and stored at $-80^\circ C$ until used for antioxidant enzyme activities and lipid

peroxidation (MDA) assays. The other part of kidney tissue was promptly washed with normal saline and stored in 10%v/v buffered formalin and then processed further for histopathological studies.

Biochemical Assessment

Serum creatinine, serum uric acid, Blood Urea Nitrogen (BUN) and serum urea [16] were estimated using commercially available kits of Span Diagnostics Ltd., India.

Biochemical estimation of markers of oxidative stress

Reduced glutathione (GSH) level was determined in the kidney tissue homogenates according to Ellman method [17], enzymatic antioxidant catalase (CAT) activity were also assessed according to Aebi *et al.*, method [18]. Glutathione peroxidase was assayed according to the procedure of Hafeman *et al.*, method [19] with some modifications. Malondialdehyde (MDA) level was analyzed by estimation of the produced thiobarbituric acid reactive substances (TBARS) by the method of Buege and Aust.[20] Glutathione reductase activity was measured according to previous reports [21].

Histopathological study

On completion of the regimen animals were sacrificed kidneys were dissected out and fixed in 10% buffered neutral formalin solution and further processed to obtain of paraffin blocks. Five-micron thick paraffin sections were prepared and routinely stained with Hematoxylin and Eosin (H&E) and examined for the histopathological changes using the light [22] microscope.

Statistical analysis

The obtained results were analyzed for statistical significance using one-way ANOVA followed by Dunnet test using the graph pad statistical software for comparison between different experimental groups. P-values < 0.001 were considered statistically significant.

RESULTS AND DISCUSSION:

The weight of kidney of rats from toxin group were significantly ($p < 0.0001$) increased when compared with normal control group. Treatment with extract of rhizomes of *Acorus calamus* prior to $AlCl_3$ intoxication has shown a dose dependant protection. (Table-1), Table-1 suggests that MEAC administration during or after $AlCl_3$ was found to protect against increased kidney weight in rats induced by $AlCl_3$.

Table-1: Effect of Methanolic Extract of Rhizomes of *Acorus calamus* on organ weight in Aluminium chloride induced oxidative stress in rats

Groups	Rats administered with respective doses	Kidney(gm)
I	Control	1.31
II	$AlCl_3$ treated (40mg/kg (oral))	1.96 [#]
III	Vitamin E + $AlCl_3$ (100mg/kg+ 40mg/kg (oral))	1.86 ^{***}
IV	Methanolic extract of AC + $AlCl_3$ (100mg/kg+40mg/kg (oral))	1.87 [*]
V	Methanolic extract of AC + $AlCl_3$ (200mg/kg+40mg/kg (oral))	1.72 ^{**}
VI	Methanolic extract of AC + $AlCl_3$ (400mg/kg+40mg/kg (oral))	1.28 ^{***}

N.B. Values are expressed as mean \pm SEM, n=6. Using t-test, the intergroup variation between various groups was conducted by graph pad Prism software & Data were analyzed by using one way analysis of variances (ANOVA). Values are expressed as mean \pm SEM. * $p < 0.05$, ** $p < 0.01$, and *** $p < 0.001$ as compared to $AlCl_3$ treated group (Group II) [Groups III to VI were compared with Group II], # $p < 0.001$ as compared to Control group (Group I) [Group II was compared with Group I].

Biochemical results

Oral administration of $AlCl_3$ to Wistar albino rats for 35 days resulted in significant increase ($P < 0.001$) in urea, creatinine, uric acid, BUN levels when compared with the other experimental groups group. The co-treatment of rats with $AlCl_3$ and Vitamin-E, MEAC for the same period improves kidney status and retained the aforementioned parameters towards the normal level when compared with the $AlCl_3$ treated group. (Table-2, 3)

Table-2: Effect of Methanolic Extract of Rhizomes of *Acorus calamus* in Serum Biochemical Parameters for Nephroprotective activity in Aluminium chloride Induced Oxidative stress in Rats:

Groups	Urea (mg/ml)	Creatinine (mg/ml)
I	48.16±0.44	1.22±0.15
II	70.99±0.39 [#]	3.00±0.071 [#]
III	55.09±0.30 ^{***}	1.02±0.005 ^{***}
IV	59.11±0.26 [*]	2.095±0.10 [*]
V	56.61±0.24 ^{**}	1.894±0.09 ^{**}
VI	55.30±0.42 ^{***}	1.095±0.10 ^{***}

N.B. Values are expressed as mean ±SEM, n=6. Using t-test, the intergroup variation between various groups was conducted by graph pad Prism software & Data were analyzed by using one way analysis of variances (ANOVA). Values are expressed as mean ± SEM. * $p < 0.05$, ** $p < 0.01$, and *** $p < 0.001$ as compared to AlCl₃ treated group (Group II) [Groups III to VI were compared with Group II], # $p < 0.001$ as compared to Control group (Group I) [Group II was compared with Group I].

Table-3: Effect of Methanolic Extract of Rhizomes of *Acorus calamus* in Serum Biochemical Parameters for Nephroprotective activity in Aluminium chloride Induced Oxidative stress in Rats:

Groups	Uric acid (mg/ml)	BUN (mg/ml)
I	3.64	19.65
II	5.23 [#]	45.86 [#]
III	3.25 ^{***}	20.65 ^{***}
IV	4.4 [*]	24.06 [*]
V	3.78 ^{**}	28.16 ^{**}
VI	3.65 ^{***}	22.04 ^{***}

N.B. Values are expressed as mean ±SEM, n=6. Using t-test, the intergroup variation between various groups was conducted by graph pad Prism software & Data were analyzed by using one way analysis of variances (ANOVA). Values are expressed as mean ± SEM. * $p < 0.05$, ** $p < 0.01$, and *** $p < 0.001$ as compared to AlCl₃ treated group (Group II) [Groups III to VI were compared with Group II], # $p < 0.0001$ as compared to Control group (Group I) [Group II was compared with Group I].

The effects on some components of the oxidative system in the kidney of Wistar albino rats after 35 days of exposure to AlCl₃ and MEAC are represented in (Table-4). There was a significant depletion of GSH level, GPx, Catalase and Glutathione reductase activities with concurrent significant elevation in the MDA level in the kidney tissues of orally exposed rats to AlCl₃ when compared with the other experimental groups.

Vitamin-E, MEAC administration along with AlCl₃ ameliorate the deleterious effects produced by Al via improvement of antioxidant status, causing elevation of GPx, GSH, GR and Catalase levels and a significant decrease in the levels of MDA when compared with AlCl₃ treated group. Notably, enhanced antioxidant level in the extract treated groups than normal indicates the high antioxidant potential of MEAC.

Table-4: Effect of Methanolic Extract of Rhizomes of *Acorus calamus* on Antioxidant parameters in Aluminium chloride Induced Oxidative Stress in Rat Kidney

Groups	MDA (nm/gm)	GSH ($\mu\text{g}/\text{mg}$)	Catalase (K/min)	GR(u/ml)	GP _x ($\mu\text{g}/\text{mg}$)
I	152.7 \pm 0.84	24.5 \pm 0.5	21.32 \pm 1.0	20.33 \pm 0.60	36.33 \pm 0.5
II	422.12 \pm 1.4 [#]	12.5 \pm 0.5 [#]	10.5 \pm 0.5 [#]	11.83 \pm 0.49 [#]	22.16 \pm 0.47 [#]
III	148.05 \pm 1.08 ^{***}	36.7 \pm 0.5 ^{***}	18.71 \pm 0.5 ^{***}	22.88 \pm 0.92 ^{***}	32.33 \pm 0.55 ^{***}
IV	178.1 \pm 1.48 [*]	25.53 \pm 0.5 [*]	14.5 \pm 0.5 [*]	15.51 \pm 0.42 [*]	24.01 \pm 0.36 [*]
V	168.35 \pm 0.84 ^{**}	27.52 \pm 0.5 ^{**}	15.52 \pm 1.0 ^{**}	17.2 \pm 0.5 ^{**}	26.35 \pm 0.33 ^{**}
VI	160.35 \pm 0.93 ^{***}	30.5 \pm 0.5 ^{***}	16.15 \pm 0.5 ^{***}	20.53 \pm 0.42 ^{***}	30.33 \pm 0.5 ^{***}

N.B. Values are expressed as mean \pm SEM, n=6. Using t-test, the intergroup variation between various groups was conducted by graph pad Prism software & Data were analyzed by using one way analysis of variances (ANOVA). Values are expressed as mean \pm SEM. * $p < 0.05$, ** $p < 0.01$, and *** $p < 0.001$ as compared to AlCl₃ treated group (Group II) [Groups III to VI were compared with Group II], # $p < 0.001$ as compared to Control group (Group I) [Group II was compared with Group I]

Histopathological Results

Histology of the Kidney in the control rats showed normal glomeruli with an intact bowman's capsule and proximal convoluted tubule. (Group-I) kidney sections of the AlCl₃ intoxicated group, (Group-II) showed modest congestion of blood vessels, necrosis of the renal cells, degeneration of glomeruli, intrarenal arterial vessel showed modest thickening of the walls, and degree of tubulointerstitial damage. Rats receiving AlCl₃ then Vit-E (Group-III) showed intact renal cortex,

preserved cellularity of renal corpuscles, and intact renal tubules. The histomorphology of rats treated with AlCl₃ then MEAC (100mg/kg) (Group-IV) showed degenerated glomeruli were observed and edema of the renal tubules) kidney sections of rats receiving AlCl₃ then MEAC (200mg/kg) (Group-V) showed moderate Congestion is present and glomerular degeneration, along with tubulointerstitial damage. Kidney sections of rats receiving AlCl₃ then MEAC (400mg/kg) (Group-VI) showed minimal glomerular damage.

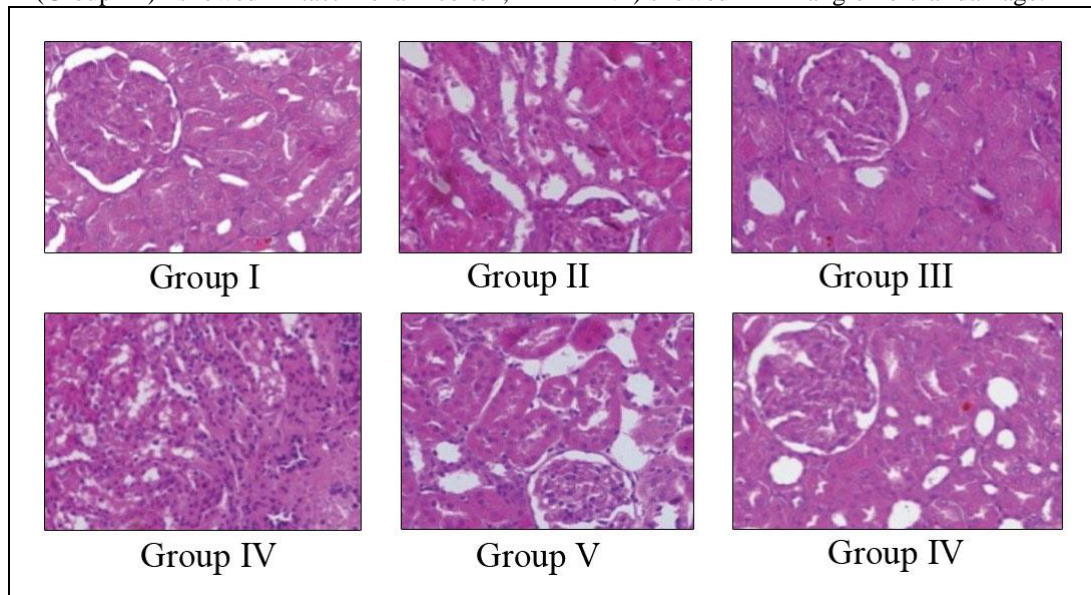


Figure-I: Histopathological changes in the kidney tissue of experimental groups

CONCLUSION:

Acorus calamus has strong antioxidant activity and this activity may be responsible for the Nephroprotective activity against Aluminium chloride induced renal damage. However, further studies on the active compounds and their biochemical mechanisms which may attribute to

the Nephroprotective effects of *Acorus calamus* are necessary to be done.

Conflicts of Interest: The author declares that they have no conflicts of interest.

ACKNOWLEDGEMENTS:

The authors are thankful to the management of Malla Reddy College of Pharmacy, for providing the required facilities to carry out the research work. We are thankful to Dr.H.Ramakrishna, HOD, Department of Botany, Osmania University, Hyderabad for authentication of the plant.

REFERENCES:

1. E. Inan-Eroglu and A. Ayaz, "Is aluminum exposure a risk factor for neurological disorders" *Journal of Research in Medical Sciences* 2018; 2: 1-51.
2. Al Kahtani, AM, Abdel-Moneim, MA, El-Sayed, MW (2014). The influence of taurine pretreatment on aluminum chloride induced nephrotoxicity in Swiss albino mice. *Histopathology* 2014;29: 45-55
3. Farina, M; Rotta, L N, Soares, F A. A, Jardim, F, Souza, DO, Rocha, J BT. Hematological changes in rats chronically exposed to oral aluminum. *Toxicology* 2005; 209(1):29-37.
4. Stohs SJ, Bagchi D, Hassoun E, Bagchi M. Oxidative mechanisms in the toxicity of chromium and cadmium ions. *Journal of Environmental Pathology, Toxicology and Oncology* 2000;20:77-88
5. Mailloux, R J; Lemire, J, Appama, V D. Hepatic response to aluminum toxicity: dyslipidemia and liver disease. *Exp. Cell. Res* 2011; 317(16): 2231-8.
6. Nan, Z, Ping, L, Lina, H. Protection of aluminum chelating agent against cardiac toxicity in rats exposed to aluminum chloride. *J. Shandong Univ. (Health Sci.)* 2009; 4(8): 125-7.
7. Lai XY, Liang H, et al. A survey of the studies on chemical constituents and pharmacological activities of *Acorus* plants. *Zhongguo Zhong Yao Za Zhi* 2002; 27: 198.
8. Maiti K, Mukherjee K, et al. Enhanced therapeutic benefit of quercetin-phospholipid complex in carbon tetrachloride induced acute liver injury in rats: a comparative study. *Iranian Journal of. Pharmacology* 2005; 4: 84-90.
9. Cesspooch L Native American Traditional Medicine and Diabetes: *Acorus calamus* L. A Sacred Medicinal Plant of the Native Cree 2005.
10. Mehrotra S, Mishra K, et al. Anticellular and immunosuppressive properties of ethanolic extract of *Acorus Calamus* rhizome. *International Immunopharmacology* 2003; 3: 53-61.
11. Shoba FG and Thomas M .Study of antidiarrhoeal activity of four medicinal plants in castor oil induced diarrhoea. *Journal of Ethno pharmacology* 2001; 76: 73 – 6.
12. Parab RS and Mengi SA. Hypolipidemic activity of *Acorus Calamus* L. in rats. *Fitoterapia* 2002; 73: 451-455.
13. Ignacimuthu S, Ayyanar M, et al. Ethnobotanical investigations among tribes in Madurai District of Tamil Nadu (India). *J. Ethnobiology. Ethnomed* 2006; 2: 25.
14. Singh G and Upadhyay RK Essential oils – a potent source of natural pesticides. *Journal of Scientific and Industrial Research* 1993; 2: 676-683.
15. Lee JY, Yun BS, et al. Antifungal activity of b-asarone from rhizomes of *Acorus gramineus*. *Journal of Agriculture and Food Chemistry* 2004; 52: 776-780.
16. McGraw LJ, Jage AK, et al. Isolation of b-asarone, an antibacterial and anthelmintic compound, from *Acorus Calamus* in South Africa. *South African J. Bo* 2002; 68: 31– 35.
17. Shirwaikar, A., D. Issac and S. Malini, Effect of *Aerva lanata* on cisplatin and gentamicin models of acute renal failure. *Journal of Ethnopharmacology* 2004; 90: 81-86.
18. Ellman, G L. Tissue sulfhydryl groups. *Archives of Biochemistry and Biophysics* 1959; 17: 214-226
19. H. Aebi, "Catalase in vitro," *Methods in Enzymology* 1984; 105: 121-126.
20. Rotruck, J.T., Pope, A.L. and Ganther, H.E., Swanson, A.B., Hafeman, D.G., and Hoekstra, W.G. Selenium: Biochemical role as a component of glutathione peroxidase. *Science* 1973; 179: 588-590.
21. Buege, J A, Aust, S D (1978). Microsomal lipid peroxidation. *Methods Enzymology* 1978; 52: 302-310.
22. Mavis, R.D. and Stellwagen, E. *Journal of Biological Chemistry* 1968; 243:809-814.