



CODEN [USA]: IAJPBB

ISSN : 2349-7750

INDO AMERICAN JOURNAL OF PHARMACEUTICAL SCIENCES

SJIF Impact Factor: 7.187

<http://doi.org/10.5281/zenodo.4446557>
Available online at: <http://www.iajps.com>

Research Article

PERVASIVENESS OF DENTAL TRANSPOSITION AMONG PAKISTANI'S POPULATION WITH AN EMPHASIS ON DISTRIBUTION OF DIFFERENT TYPE OF TRANSPOSITIONS IN MAXILLA AND MANDIBLE

¹Usaara Fatima, ²Dr Marriam Bakhtawar, ³Dr. Saira Jabeen

¹Frontier Medical and Dental College, Abbottabad, ²Women Medical Officer, Sheik Zayed Medical College and Hospital Rahim Yar Khan, ³LMDC.

Article Received: November 2020 Accepted: December 2020 Published: January 2021

Abstract:

Aim: For the exploration of the pervasiveness of dental transposition among Pakistani's population with an emphasis on distribution of different type of transpositions in maxilla and mandible.

Study design: This research and study was carried out in Department of orthodontics Lahore Medical and Dental Collage from December 2017 to November 2018.

Materials and Methods: All about of this study done with panaromic radiographs of 728 adolescent patient (276 males, 452 females). They were treated in our clinic and they were included in study below. For each patient variables like age, sex, presence of tooth transposition, type, location and classification of tooth transposition recorded.

Results: Proper category of tooth transposition was found in 07 subjects present with 0.96% frequency of this abnormality. These 7 patient have 8 transposing teeth in general. The ratio of female to male is 71.4% to 28.6%. The problem manifest in maxilla. It was present in 5 of the patient (71.42%) 4 with unilateral and 1 with bilateral manifested type. Two of the patient had exchanged position of teeth in mandible.

Conclusion: In a sample of Pakistani population the tooth transposition was found in 0.96% and transposition between upper canine and first premolar was the most commonly observed transposition.

Key words: Maxilla, tooth transposition, mandibulla, lateral incisor, canine.

Corresponding author:**Usaara Fatima,**

Frontier Medical and Dental College, Abbottabad.

QR code



Please cite this article in press Usaara Fatima et al, *Pervasiveness Of Dental Transposition Among Pakistani's Population With An Emphasis On Distribution Of Different Type Of Transpositions In Maxilla And Mandible.*, *Indo Am. J. P. Sci.* 2021; 08(1).

INTRODUCTION:

Type of explosion variance where there is either an exchange of position between two adjacent teeth is defined as transposition, or the development and eruption of a tooth in a position normally occupied by another non-adjacent tooth.[1] Transposition is classified as complete, where it involves both the crown and the root (with the roots of the transposed teeth parallel to each other), or incomplete, where the crown alone is involved.[1-4] Transposition of teeth should not be confused with ectopic eruption. By definition, all transpositions are ectopic eruptions but not all ectopic eruptions result in transposition [5]. It is a rare condition with a reported prevalence of 0.13-0.4% in the general population [1],[4],[6-9].

Patients with tooth transposition may present with concomitant dental anomalies including hypodontia (most often missing the permanent upper lateral incisor), dilacerations, and abnormalities of tooth size/shape (such as peg-shaped teeth).[1],[10] In addition, retention of deciduous teeth (especially the primary canine) is often observed, along with the presence of malaligned adjacent teeth.[1],[10],[11] Transposition affects teeth of either the maxillary or the mandibular arch, and only rarely occurs simultaneously in both arches. Overall, it is more frequently observed in the maxilla than in the mandible.[1-4],[10],[11]

Table 1 shows the types of transpositions most frequently seen in maxillary arch.

Table 1: Classification of transposition of permanent maxillary teeth in decreasing order of frequency.⁴

1. Canine–first premolar.
2. Canine–lateral incisor.
3. Canine on the site of first molar.
4. Lateral incisor–central incisor.
5. Canine on the site of central incisor.

The dental transposition between the canine and the first premolar is a genetic abnormality, according to Peck and Peck [1, 12] and Chattopadhyay [8]. It is multifactorial inherited from a polygene type. It is often manifested unilaterally and there is a difference between the prevalence among male and female patients. Burki *et al.* [13] report that transposition is more often observed in combination with peg-shaped lateral, hypodontia, ankylosis of primary teeth, or severe rotation of permanent teeth. Shapira [3] reports that 18.5% of patients with transposition have one or more missing teeth. Because of its genetic nature Ciarlantini and Melsen [14] ask the question “Do we have to treat the dental transposition or do we have to accept it?”. Authors like Babacan [15], Demir [16], Filho [17] offer their own techniques of attempts to treat this rare dental abnormality.

FREQUENCY:

Dental transposition is observed in 1 of 300 orthodontic patients as reported by Burki and Munawwar [13]. According to Mattos [18] the dental transposition frequency is 0.4%. That includes both unilateral and bilateral in ratio of 1:4 and the left

sided transpositions are more frequent than the right sided ones. Gebert’s [19] research on the problem reveals that the most frequent transposition is between canine and first premolar – it can reach up to 80%, compared to the transposition between lateral incisor and canine, which reaches up to 20%. Roman [20] studies 700 orthodontically treated patients and finds out that the rate of dental transposition is 0.83%.

Celikoglu [21] studies dental transposition among the Turkish nation and discovers a rate of 0.27% and ratio of female/male 2.2/1. In his research from 2011 Synodinos [22] reports that the frequency of dental transposition is from 0.13% to 0.4%. He quotes Thilander (1968) with data from the Swiss nation with rate of 0.30%, Ruprech’s survey is on Arabic patients in Europe – 0.13% and Burnett (1999) – 0.51%. Ely’s [23] research is made among 75 patients diagnosed with dental transposition. They had a total of 85 transposition teeth. A significant research in the orthodontic literature is made by Papadopoulos *et al.* [24] in 2010. They found out that the prevalence of dental transposition was approximately 0.33%. The most commonly observed

is unilateral.

The aim of this study is to reveal prevalence of dental transposition among Pakistani's population presenting in OPD of nishter institute of dentistry Multan. It is more often observed in male than in female patients.

MATERIAL AND METHODS:

We analyzed every clinical case, which includes: X-ray (orthopantomography-OPG, photos and model casts of the patient. This study is based on 728 patients, who were orthodontically treated at our clinic from 2017 to 2018. All of the patients are between the age of 5 and 21, which means that they are in their growing period. The average age of the patients we studied was 13.85 ± 3.58 . Male patients are 276 (37.9%) and female patients are 452 (62.08%), respectively. All of the patients had dento-alveolar abnormalities. Most of the patients among the males are between the age of 11–16 years old (60 cases), followed by 5–10 years (121 cases). Most of the female patients are between 11–16 years old (279 cases), followed by 17–21 years old patients (103 cases).

We made a division of the patients by the following factors: presence of teeth that are in exchanged position. Type of transposition: unilateral or bi-lateral; in maxilla or in mandibulla; left or right sided; if the transposition is between canine and first premolar or lateral incisor. We reported the relative orthodontic deformations that are most commonly seen among patients diagnosed with dental transposition. Our survey includes rare cases of pseudo-transposition of teeth.

Inclusion criteria:

Main focus of the study was incidence of different types of dental transposition in maxilla and mandible among orthodontic patients. Study subjects all of the patients between the age of 5 and 21, which means that they are in their growing period. The average age of the patients we studied was 13.85 ± 3.58 . Patients who were willing and were present in duration of the orthodontic treatment of dental transposition were included in the study.

Exclusion Criteria

This study excludes dental abnormalities associated with dental transpositions and treatment strategies

and management of these orthodontic cases, subjects who were not willing for participate.

RESULTS:

There is an absence of cases with transposition between lower right premolar and canine in our survey. We report single cases of transposition between lower right canine and lateral incisor, as well as lower left canine and first premolar and canine and lateral. The patients diagnosed with transposition are 7(0.96%). Five of them are with unilateral transposition and 2 are with bilateral. These 7 patients have a total of 8 teeth that are in transposition. The ratio among female and male who are diagnosed with dental transposition is 71.4% to 28.6%. The problem is most commonly manifested in the upper jaw, 5 patients are diagnosed with transposition in the maxilla (71.42%). 4 of them are with unilateral type and 1 with bilateral. Two of the patients have transposition in the mandible. One of the clinical cases are with bilateral transposition between the upper canines and first premolars. These patients present 14.2% of all the patients with transposition. Bilateral transposition is observed in 2 of the female patients. One of them is diagnosed at the early age of 9. The diagnosis was based on X-ray, made before orthodontic treatment concerning another abnormality.

The unilateral type of dental transposition was observed in 2 cases (36.4%) between upper canine and first premolar, in 2 cases upper canine – lateral incisor (36.4%), 1 cases with exchange between lower canine and lateral incisor (18.2%) and 1 case with dental transposition of the lower canine and first premolar Exchanged upper right first premolar with canine is presented in 3 cases (35.3%) out of 7. This is the most common type of dental transposition. From these cases one with bilateral manifestation and four with unilateral. They are followed by transposition between upper left canine with lateral incisor – 2 cases (23.5%). From these cases 2 are with unilateral manifestation and one with bilateral. We report one cases of transposition between upper right canine with lateral (11.80%) and one cases of transposition between upper left first premolar with canine (11.80%) (fig. 2).

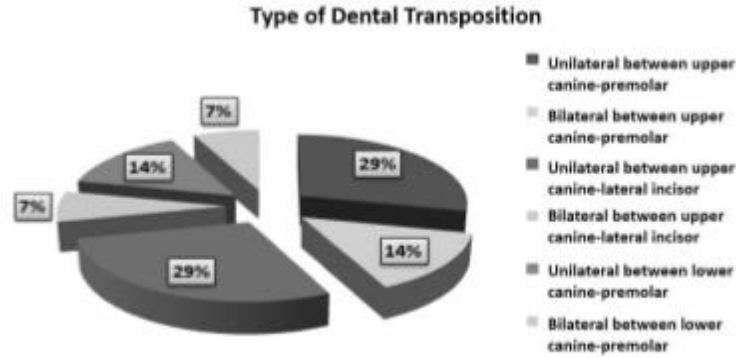


Fig. 2. Prevalence of different type of transposition

According to this factor we do not find a significant difference between the prevalence of transposition on the two sides of the face.

DISCUSSION:

Which is observed among Pakistani's orthodontic patients with prevalence of 0.96% the abnormality is dental transposition. This rate is normal, compared to the one reported in the other European countries (0.2–1.5%).

To date, there have been few investigations of transpositions in different ethnic groups. The prevalence of transpositions has been reported as 0.14-0.38% in Nigeria, [25],[26] 0.41% in India, [8]

0.13-0.64% in Greece, [27],[28] 0.09% in Germany, [29] 0.13% in Saudi Arabia, [30] and 0.27-0.33% in Turkish [31],[32] populations. All these figures suggest that tooth transposition might be considered a rare phenomenon. Tooth transposition is a peculiar type of ectopic eruption in which each ectopic tooth changes the normal order of the tooth sequence within the same dental arch.

According to data from epidemiological studies, the prevalence of maxillary canine to first premolar transposition ranges from 0.03-0.51% (Table. 2)[6,34,30]

Table 3: Prevalence of maxillary canine-first premolar transposition.

Study	Population	Prevalence (%)
Thilander and Jakobsson (1968) ⁶	Swedish schoolchildren	0.03
Ruprecht <i>et al</i> , (1985) ²⁶	Arabian dental patients	0.13
Bumett (1999) ²⁷	Composite African sample	0.51

There seem to be no significant difference in the prevalence of tooth transposition between males and females. However, contrast observations have been found in the literature. Some studies [8],[33] reported that transpositions were more commonly observed in males while some reported the opposite finding. [13],[16],[17]

Transposition can be detected quite easily even by means of clinical examination and palpation of the area of the roots of the corresponding teeth. For confirmatory diagnosis, a radiographic survey by means of panoramic or intraoral periapical

radiographs is of more useful. The age of the patient is very important during diagnosis as tooth transposition cannot be securely diagnosed in individuals aged younger than 7 years. [24]Although some of these authors proposed a hypothesis that gender-related genes may be responsible for tooth transposition but this is yet to be confirmed. Chattopadhyay and Srinivas [2] stated that higher female predilection might be associated with higher number of females seeking orthodontic treatment. This is in agreement [32],[11],[3] with this study where a higher male prevalence was observed and in contrast with other studies [8],[33] where females

were more frequently identified.

The high bone density of the mandible might be responsible for a prohibition of the phenomenon of tooth transposition, and thus the higher incidence of maxillary occurrence. [24] In all three cases, transposition occurred in the maxilla coinciding with the reported literature. [4],[31],[32],[24]. Transposition can affect either the maxillary or mandibular dentition but has been reported more commonly in the maxilla than mandible.

It was observed from various studies [31],[32],[24] that the unilateral occurrence of tooth transposition is more frequent than the bilateral. In all three cases reported here, transposition occurred unilaterally and this is in agreement with previous studies. [31],[32],[24] The localization of tooth transposition on either the left or right quadrant with a predilection for the maxilla or mandible, has been identified in previous studies. [25],[26],[27],[28] In contrast, previous studies [11],[3],[12],[34],[35] identified that most of the maxillary transpositions were found on the left side and all of the mandibular transpositions on the right side. However, this present case report identified all three transpositions on the right.

Tooth transpositions most frequently involve the canine tooth, which may be transposed with either the first premolar or the lateral incisor. [32],[24],[33],[11] Shapira and Kuftevec [3] explained this high incidence with the canine's longest period of development and longest path of eruption. Similarly, in this case report, canines were involved. Transpositions that do not involve the canine teeth, such as the central and lateral incisor transpositions, are extremely rare. In one patient, maxillary lateral incisor was transposed with central incisor thereby being a rare case.

Among the five Peck and Peck's [4] classification of tooth transpositions, maxillary canine-first premolar transposition is the most commonly seen transposition reported with prevalence of 0.135-0.51%. [8],[30],[34] Celikoglu et al.,[32] and Yilmaz et al.,[31] reported 57.9% and 0.9% prevalence of maxillary canine-lateral incisor transposition, respectively. Our two patients exhibited maxillary central incisor- lateral incisor transposition (Mx.I1.I2) and maxillary canine-first premolar transposition (Mx.C.P1). Although the phenomenon of transposition has been identified previously in the literature, its exact etiology is still obscure and an area of controversy. Several theories have been proposed to account for this condition and includes the interchange of developing tooth buds, migration of a tooth during eruption, heredity, the presence of retained primary teeth, and mechanical interferences. [24],[3] Bone pathology, such as cyst formation and odontomas may also cause displacement and transposition of the tooth. [36] Early loss of incisors and trauma to the deciduous teeth has also been suggested as possible etiologic factors. Many types of transposition have been associated with factors that have a genetic basis including female predilection, unilateral left-side dominance, hypodontia, retained primary teeth, and peg-shaped maxillary lateral incisor teeth. It has been suggested based on research [24],[3],[36] that the fundamental etiology for dental transposition may be genetic and within a model of multifactorial inheritance. However, in a study on transposition by Yilmaz et al.,[32] a previous history of trauma was observed to be more frequent (50%) in maxillary canines than in the central incisor. Though a history of trauma was observed in one of the cases selected, it is unlikely to be an etiologic factor in the development of transposition as the trauma occurred in a non-transposition area. The exact aetiology of tooth transposition remain unclear but several explanations have been postulated (table 3)[1,4,7,8].

Table 2: Proposed aetiology of tooth transposition.

- Genetic factors
- Exchange of position between developing tooth buds
- Retention of deciduous teeth, especially the deciduous canines
- Intra-osseous migration of the developing permanent canine
- Trauma to the deciduous teeth
- Cysts or other localised pathology

Various anomalies reported with tooth transpositions are peg-shaped lateral incisors, retained deciduous canines, rotations and malpositions, dilacerations, supernumerary teeth, impacted teeth, and hypodontia.

Association of dental anomalies has been reported more frequently in transposition cases than in a normal population. [31],[32],[24],[33] Our transposition cases also showed associated anomalies

to include supernumerary teeth, root dilacerations, and retained primary canines, which is in agreement to the existing literature. [27],[31],[32]. Peck et al.,[12] found 37% of tooth agenesis in transposition cases, whereas, Yilmaz et al., [32] and Chattopadhyay and Srinivas [8] found tooth agenesis (either one or two teeth) in transpositions cases to be 33.3% and 40%, respectively. They also found a higher frequency of missing teeth in maxillary canine-lateral incisor cases. Other Indian studies [8] reported a higher frequency of peg-shaped lateral incisors in the maxillary canine-premolar transpositions (67%) and maxillary canine-lateral incisor transpositions (71%). However, Shapira and Kuftinec [3] stated that only one patient (1/65) had peg-shaped lateral incisors in their study. (Our report showed the presence of a supplemental lateral incisor in the maxillary lateral incisor-central incisor transposition case (case no. 2). A morphological and radiographical examination diagnosed the transposed tooth which appeared similar to the supplemental lateral incisor in this study. Other studies have also used these methods in differentiating these teeth. [28],[29],[30],[31] Eruption of mesiodens in the midline may have been an etiologic factor in the distal and labial displacement of the central incisor resulting in the transposition of the lateral incisor.

Yilmaz et al.,[32] showed that in 60% of maxillary canine-first premolar transpositions, root dilacerations were observed in premolars and laterals. This high frequency suggests that root dilacerations of the adjacent teeth may be a potential etiologic factor of canine-premolar transpositions. The same finding was observed in our canine-second premolar transposition case where the transposed premolar had a dilacerated root. This was also observed in the central incisor which was transposed with the lateral incisor. [27],[31],[32],[24]. Two Turkish studies [31],[32] recorded supernumerary teeth in 4.8% and 5.3% of their cases. Our two transposed cases also showed supernumerary teeth coinciding with these findings. In one case, two supernumerary teeth were located in the midline of maxilla, and in other patient, one mesiodens and one supplemental lateral incisor were present.

Deciduous canines have more often been reported to be over retained in majority of the transposition cases. [1],[31],[32],[3] Some reports [37],[38] stated that if the roots of primary canines were not resorbed, then migration of permanent canines to the incisor, second premolar or first molar area might occur. However, Peck et al.,[12] suggested, a retained primary canine is a consequence of the anomaly not its cause.

Yilmaz et al.,[32] found retained primary canines in 60% of maxillary canine-first premolar and in 22.2% of maxillary canine-lateral incisor transpositions. Our canine-premolar transposition case also showed a similar finding. Impaction of contra lateral canine was also observed in the same patient. This indicates that retained primary canines in both quadrants might be a possible etiologic factor for transposition and impaction of permanent canines but this cannot be justified.

CONCLUSION:

We found a frequency of prevalence 0.96% which more often is a result of unilateral maxillary dental transposition than bilateral. Tooth transposition manifests in various forms and may represent a condition of multifactorial etiology. We reported two cases with problems in the lower jaw. The frequency of dental transposition between upper canine and first premolar is higher, as compared to the frequency of prevalence of the upper canine and lateral incisor. Early diagnosis and detection by clinicians of a developing transposition is very important to prevent subsequent malocclusion and its attendant consequences.

REFERENCES:

1. Shapira, Y., Kuftinec, M.M. Tooth transpositions – a review of the literature and treatment considerations. *Angle Orthod* 1989; 59: 271-276.
2. Peck, L., Peck, S., Attia, Y. Maxillary canine–first premolar transposition, associated dental anomalies and genetic basis. *Angle Orthod* 1993; 63: 99-109.
3. Maia, F.A., Maia, N.G. Unusual orthodontic correction of bilateral maxillary canine–first premolar transposition. *Angle Orthod* 2005; 75: 266-276.
4. Peck, S., Peck, L. Classification of maxillary tooth transpositions. *Am J Orthod Dentofacial Orthop* 1995; 107: 505-517
5. Shapira, Y., Kuftinec, M.M. Maxillary tooth transpositions: characteristic features and accompanying dental anomalies. *Am J Orthod Dentofacial Orthop* 2001; 119: 127-134.
6. Thilander, B., Jakobsson, S.O. Local factors in impaction of maxillary canines. *Acta Odontol Scand* 1968; 26: 45-68.
7. Joshi, M.R., Bhatt, N.A. Canine transposition. *Oral Surg Oral Med Oral Pathol* 1971; 31: 49-54.
8. Chattopadhyay, A., Srinivas, K. Transposition of teeth and genetic etiology. *Angle Orthod* 1996; 66: 147-152.
9. Ely, N.J., Sherriff, M., Cobourne, M.T. Dental transposition as a disorder of genetic origin. *Eur*

- J Orthod 2006; 28: 145-151.
11. Yilmaz, H.H., Türkkahraman, H., Sayin, M.O. Prevalence of tooth transpositions and associated dental anomalies in a Turkish population. *Dentomaxillofac Radiol* 2005; 34: 32-35
 12. Plunkett, D.J., Dysart, P.S., Kardos, T.B., Herbison, G.P. A study of transposed canines in a sample of orthodontic patients. *Br J Orthod* 1998; 25: 203-208.
 13. Demir A., F. A. Bascifci, I. E. Gelgor, A. I. Karaman (2002) *JCO*, 36,
 14. Ciarlantini R., B. Melsen (2007) *AJODO*, 132, 385–394.
 15. Burki S., S. Munawwar (2004) *Pakistan Oral & Dent. Jr.*, 24, No 1, 61–63.
 16. Babacan H., B. Kilic, A. Bicakci (2008) *Angle Orth.*, 78, No 5, 954–960.
 17. Filho L., M. A. Cardoso, T. An, F. Bertoz (2007) *Angle Orth.*, 77, 167–175.35–37.
 18. Peck S., L. Peck, M. Kataja (1998) *Angle Orth.*, 68, 455–466.
 19. Mattos B., J. Carvalho, M. Matusita, A. Alves (2006) *Braz. J. Oral. Sci.*, 5, No 16, 953–957.
 20. Onyeaso CO, Onyeaso AO. Occlusal/dental anomalies found in a random sample of Nigerian school children. *Oral Health Prev Dent* 2006;4:181-6. Back to cited text no. 25
 21. Synodinos Ph., J. Polyzois (2011) *Jour. Irich Dental Assoc.*, 56, No 6, 264–267.
 22. Celikoglu M., Oz. Miloglu, Oz. Oztek (2010) *Med. Oral. Patol.*, 15, No 5, e716–e720.
 23. Roman C., M. Anisie, E. Damasaru (2005) *OHDMBSC*, 6, No 3, 24–27.
 24. Ely N., M. Sherriff, M. Cobourne (2006) *EJO*, 28, 145–151.
 25. Papadopoulos M., M. Chatzoudi, El. Kaklamanos (2010) *Angle Orth.*, 80, No 2, 275–285.
 26. Gebert T., V. Palma, Al. Henrique. <http://dx.doi.org/10.1590/2176-9451.19.1.106-112.oar>
 27. Umweni AA, Ojo MA. The frequency of tooth transposition in Nigerians, its possible aetiologic factors and clinical implications. *J Dent Assoc S Afr* 1997;52:551-4. Back to cited text no. 26
 28. Laptok T, Silling G. Canine transposition: Approaches to treatment. *J Am Dent Assoc* 1983;107:746-8. Back to cited text no. 38
 29. Shapira Y. Bilateral transposition of mandibular canine and lateral incisors: Orthodontic management of case. *Br J Orthod* 1978;5: 207-9. Back to cited text no. 37 [PUBMED]
 30. Serra-Serra G, Berini-Aytés L, Gay-Escoda C. Erupted odontomas: A report of three cases and review of the literature. *Med Oral Patol Oral Cir Bucal* 2009;14:E299-303. Back to cited text no. 36
 31. Burnett SE. Prevalence of maxillary canine-first premolar transposition in a composite African sample. *Angle Orthod* 1999;69:187-9. Back to cited text no. 34[PUBMED]
 32. Yilmaz HH, Türkkahraman H, Sayin MO. Prevalence of tooth transpositions and associated dental anomalies in a Turkish population. *Dentomaxillofac Radiol* 2005;34:32-5. Back to cited text no. 31
 33. Celikoglu M, Miloglu O, Oztek O. Investigation of tooth transposition in a non-syndromic Turkish anatolian population: Characteristic features and associated dental anomalies. *Med Oral Patol Oral Cir Bucal* 2010;15:e716-20. Back to cited text no. 32
 34. Shapira Y. Transposition of canines. *J Am Dent Assoc* 1980;100: 710-2. Back to cited text no. 33[PUBMED]
 35. Ruprecht A, Batniji S, El-Neweihi E. The incidence of transposition of teeth in dental patients. *J Pedod* 1985;9:244-9. Back to cited text no. 30
 36. Grant JE, Abu Mezier N, Dibiase AT. Maxillary first and second molar tooth transposition: A case Report. *Int J Paediatr Dent* 2006;16:227-9. Back to cited text no. 35
 37. Dahl T. [The transposition of teeth]. *Zahn Mund Kieferheilkd Zentralbl* 1976;64:267-70. Back to cited text no. 29. [PUBMED]
 38. Hatzoudi M, Papadopoulos MA. Prevalence of tooth transposition in Greek population. *Hell Orthod Rev* 2006;9:11-22. Back to cited text no. 28
 39. Kavadia-Tsatala S, Sidiropoulou S, Kaklamanos EG, Chatziyanni A. Tooth transpositions associated with dental anomalies and treatment management in a sample of orthodontic patients. *J Clin Pediatr Dent* 2003;28:19-25. Back to cited text no. 27[PUBMED].