



CODEN [USA]: IAJPBB

ISSN : 2349-7750

**INDO AMERICAN JOURNAL OF
PHARMACEUTICAL SCIENCES**

SJIF Impact Factor: 7.187

<http://doi.org/10.5281/zenodo.4906800>Online at: <http://www.iajps.com>

Review Article

**MISALIGNED SPINE BECAUSE OF DIFFERENT MUSCLES: A
LITERATURE REVIEW****Dr. Raymond L Venter**

(1BSC, 2PhD Natural Medicine)

¹Quantum University²University of Southampton UK**Article Received:** May 2021**Accepted:** May 2021**Published:** June 2021**Abstract:**

The typical sagittal curvature exemplifies proper body posture. Cervical and thoracic spines are inwardly curved (backward) (kyphosis). The pelvis is shifted forward, but the lower limbs maintain their level position. However, the optimal alignment of the body varies significantly.

The most frequently observed abnormalities of body posture in the sagittal plane are as follows: lordotic, kyphotic. One's posture affects both the skeletal and muscular systems, putting additional strain on the supporting structures. Changes in muscle length or lengthening typically manifest muscle abnormalities. However, reports indicate that when the muscles that support your body (occasionally referred to as stabilizers) are not used for an extended period, such as while you are sitting in one position, your posture may be compromised due to the hypo reaction. When the locomotor system's stability cannot be maintained, the musculoskeletal system takes over. However, it has the unintended consequence of increasing rigidity and inflexibility in the musculoskeletal system.

Keywords: *spinal misalignment, Sway-back posture, Flat-back posture, Kyphotic posture, Lordotic posture, Faults of body posture, Corrective exercises, Body posture.*

Corresponding author:**Dr. Raymond L Venter,***(BSC, PhD Natural Medicine)**Quantum University**University of Southampton UK*

QR code



Please cite this article in press Raymond L Venter et al., Misaligned Spine Because Of Different Muscles: A Literature Review..., Indo Am. J. P. Sci, 2021; 08(06).

INTRODUCTION:**Body Posture**

Posture is always determined by the upright position of the human body's body parts. Numerous bodily regions, such as the head, trunk, and lower limbs, affect the final position. While having good posture while standing is preferable, being efficient while moving is critical, as it aids in the function of the internal organs. The sagittal, coronal, and transverse planes are used to measure and discuss it. Musculoskeletal balance refers to the primary structures of the body regardless of posture (standing, sitting, lying, squatting, or slumping); it is in these positions that the muscles and their thoracic and abdominal organs function optimally. Due to the authors' emphasis on human posture, this article's definition of body posture is more constrained.

Poor posture is a term that refers to non-ideal, incorrect body posture. It is suggested that poor posture strains the supporting structures and results in inefficient balance.

The sagittal plane is the most difficult to describe, as it is considered identical to the coronal and transverse planes. Although human beings are not perfectly symmetrical, the sagittal plane has been simplified in this article.

The typical sagittal curvature exemplifies proper body posture. Cervical and thoracic spines are inwardly curved (backward) (kyphosis). Because his chin is positioned just above his chest at eye level, this individual's head is always level. The pelvis is in an anterior position, and the legs are in their normal positions.

The external auditory meatus should be the starting point, followed by the T7, the malleoli, and finally, the lateral condyle of the vertebrae. This is an excellent frame of reference that connects the central area to the supporting area.

Similarly, in the majority of cancer patients, particularly breast cancer patients, women who undergo mastectomy alone exhibit differences in the vertical alignment of the trunk, with greater asymmetry between the acromion and greater trochanter, which can result in trunk rotation. Following breast cancer surgery, the surgical technique appears to make a difference. Additionally, lymphedema appears to exacerbate asymmetries and post-mastectomy posture changes. Mazzocchi et al. demonstrated that the head centre of mass varied significantly in the mediolateral direction, indicating that the head was repositioned. According to some

researchers, the increased weight of the breasts results in several spinal postural changes, including dorsal kyphosis and anterior shoulder dislocation.

It does not adequately explain a good sagittal plane posture. Additionally, describing non-ideal behaviors can be difficult. This paper will demonstrate the sagittal plane's misalignments.

Non-structural sagittal misalignments**Principal types of sagittal postural misalignments**

In both children and adults, the most common sagittal plane misalignments are (1) lordotic, (2) flat-backed and swaybacked, and (3) posture, and (4) flatback. The biomechanics and muscles to be improved will be determined. Thus, before discussing faulty postures, it is necessary to define the concept of functional muscle classification.

Bergmark and Richardson classified functional muscles: Bergmark and Richardson et al. investigated functional muscle specificity. Numerous research studies support the notion that common stressors (e.g., changes in joint load or use, including ballistic exercises), reflective inhibition or excitation, and muscle shortening influence muscle strength gains—reflexivity results in hyperactivity and a possible reduction in range of motion. Muscle shortening is typically associated with decreased flexibility, but this will be discussed in greater detail in the other paper.

Muscle groups maintaining good body posture

They proposed categorizing skeletal muscles into two categories: (1) stabilizing or mobilizing, or local muscles, also known as multiarticular muscles; and (2) mobilizing, or multiarticular muscles (see below). According to the authors, effective cooperation between these two muscle groups enables load transfer from the thoracic to the pelvic region while minimizing stress on the lumbar segments during functional movements.

According to Bergmark and Richardson et al., it includes the multifid, transversus abdominis, intertrans, interspinal, pelvic fascia, internal oblique, central erector spinae, and diaphragm muscles. These muscles are capable of controlling the joint and vertebral position. Stabilizers provide global and segmental stability for the spine by decreasing their activity, thereby decreasing the muscle strength of contractions (hypoactivity). This condition may be brought on by joint pain, daily routines, or a lack of gravitational loading.

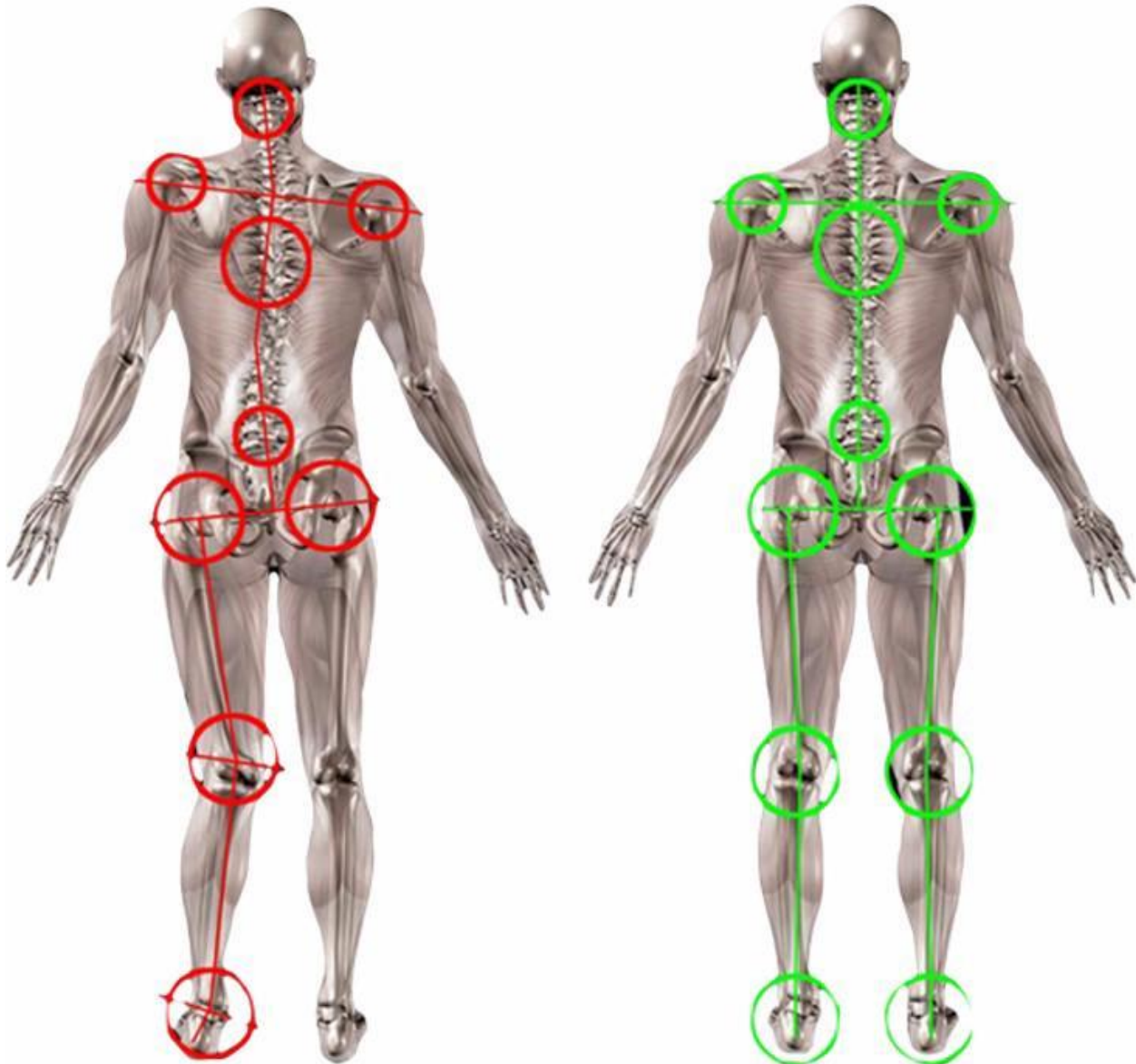
Global muscles are commonly used to refer to the trunk and limb-based multi-joint muscles. Numerous joints rely on this muscle as a stabilizer and force producer. This is the most ancient. Stabilizers and mobilizers are both included in the global muscles.

Antigravity muscles are included in the global stabilizer muscle group. Gluteus maximus, erector spinae These muscles assist in maintaining the joint's position while it is being moved.

Muscles such as the erector spine, internal and external oblique, anterior quadratus lumborum, tensor fasciae latae, and tensor latae are mobilizers.

Muscle groups functioning in faulty body posture

Gravity exposure, such as standing or walking, is critical for the skeleton's muscles to function properly. They eventually deteriorate if they are not used, as when you sit or lie for extended periods. When the locomotor system is unstable, mobilizing muscles to take over to compensate. However, such compensatory measures increase their activity and decrease their flexibility, resulting in chain reactions throughout the musculoskeletal system.



Lordotic posture

A lordotic posture differs from a pelvic inversion (anterior tilt). If the pelvis is forward, the hips will be flexed. plantararchesisomerosis of the result of having this knee position

When you stand on your tip-toes, the facets get crushed. Of the leg that causes anterior compartment syndrome, the headline may run in front of the baseline. It is listed in Table 1.

Table 1

The position of body parts in the lordotic posture

Part of the body	Position
Head	Neutral
Cervical spine	Normal curve = physiologically convex anteriorly (lordosis)
Thoracic spine	Normal curve = physiologically convex posteriorly (kyphosis)
Lumbar spine	Hyperextended (hyperlordosis)
Pelvis	Increased anterior tilt
Hip joints	Relatively flexed

Functional state of muscles in the lordotic posture

These muscles are augmented in length. The gluteus Maximus is an inactive muscle. This continues to compensate for the gluteus Maximus for pelvic and hip joint maintenance.

The quadriceps and one-joint muscles, specifically the rectapularis and tensor fasciae latae, are shortened. However, clinically, the psoas should be divided into two muscles: the hyperopic (normally diaphragmatic) and the hyperactive (usually psoas). The quadratus lumborum is divided into two sections: the medial and lateral quadratus lumborum. The medial quadratus lumborum mens is responsible for spinal stability, whereas the lateral quadratus lumborum mens, which involves trunk motion, is prone to hyperactivity.

According to both literature and biomechanical analysis, the Erector Spina is notable for its presence in the lumbar region of the spine. According to the authors' research, this muscle rarely shortens. Due to the possibility that this is a result of how much time we spend sitting, the erector spinae is constantly stretched. When it comes to the legs, hyperextension of the knees favors hyperextension of the soleus and hip flexors, which both have the opposite effect on the long adductors (Table 2)

Table 2

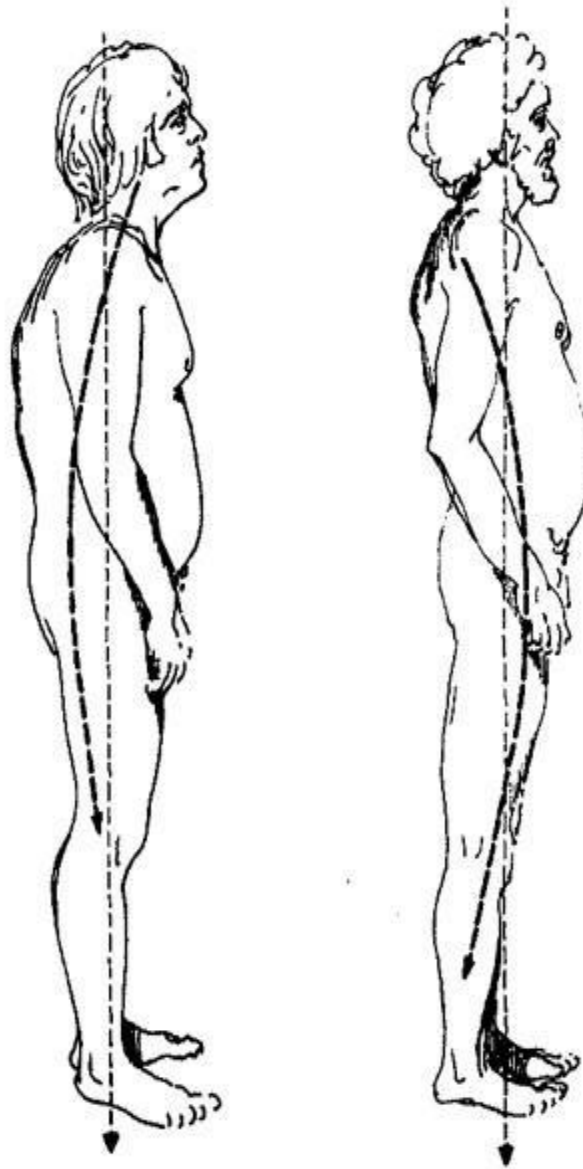
Functional characteristics of muscles in the lordotic posture

Muscle	Lengthened	Shortened	Hypoactive	Hyperactive
Rectus abdominis	+			+
Abdominal internal oblique (anterior part)	+			+
Abdominal internal oblique (posterior part)	+		+	
Abdominal external oblique	+			+
Gluteus maximus	+		+	
Gluteus medius (posterior part)	+		+	
Hamstrings	+			+
Erector spinae part lumbar (in sitting)	+		+	
Erector spinae part lumbar (in standing)		+	+	
Quadratus lumborum (medial part)		+	+	
Quadratus lumborum (lateral part)		+		+
Iliacus		+	+	
Psoas		+		+
Two-joint hip flexors		+		+
Gastrocnemius		+		+
Soleus		+	+	

Note: the symbol “+” means that the muscle meets a certain criteria

Kyphotic posture

The kyphotic posture is an abnormal posture that is distinguished from the normal one by the following characteristics: (1) increased thoracic kyphosis, (2) protraction of the head, (3) flattening or reversing the lower cervical lordosis, (4) increased upper cervical lordosis, and (5) shoulder and scapular protraction.



In the kyphotic posture, the headline is shifted anteriorly to the thoracic spine, lumbar vertebral bodies, and hip and knee joint axes. Typically, the baseline follows the headline. The kyphotic posture is described in detail in Table 3.

Table 3

The position of body parts in the kyphotic posture

Part of the body	Position
Head	Protracted (moved forward)
Cervical spine	Upper part: extended (hyperlordosis) Lower part: flexed (hypolordosis or kyphosis)
Scapulae	Abducted (moved laterally)
Shoulders	Protracted (moved forward)
Thoracic spine	Increased flexion (hyperkyphosis)
Chest	Tilted downward, sometimes flattened
Sternum	Tilted downward
Thoracic outlet	Increased obliquity
Lumbar spine	Neutral
Pelvis	Neutral
Hip joints	Neutral

Functional state of muscle in the kyphotic posture

Contraction of the rhomboids, erector spinae, and lower and middle trapezius

Suboccipital, sternocleidomastroid, pectoral, and lats are the four. The longissimus dorsi, on the other hand, may be located only near the lesser tubercle of the humerus, implying that only internal rotation of the shoulder musculature of the humerus is possible. By contrast, increased thoracic kyphosis results in medial latissimus dorsi lengthening.

Examine the abdominal muscles, and these chest muscles will need to be altered during the selection of corrective exercises (Table 4).

Table 4

Functional characteristics of muscles in the kyphotic posture

Muscle	Lengthened	Shortened	Hypoactive	Hyperactive
Erector spinae (thoracic part)	+			+
Rhomboideus major and minor	+		+	
Serratus anterior	+		+	
Trapezius (middle and lower parts)	+		+	
Latissimus dorsi (medial part)	+			+
Suboccipital		+		+
Sternocleidomastoid		+		+
Scaleni		+		+
Latissimus dorsi (area of insertion)		+		+
Trapezius (superior part)		+		+
Pectoralis minor and major		+		+
Rectus abdominis		+		+
Abdominal internal oblique (anterior part)		+		+
Abdominal internal oblique (posterior part)		+	+	
Abdominal external oblique		+		+

Note: the symbol “+” means that the muscle meets a certain criteria

Kyphotic-lordotic posture

Certain individuals may exhibit both sagittal and kyphotic postures. The effects of kyphosis and lordosis augment the musculoskeletal system.

They would like to emphasize that difficult kyphotic planning may occur. For example, in lordosis, the abdominal muscles are stretched and relaxed, whereas,

in kyphosis, the abdominal muscles are stretched and relaxed. While it is beyond the scope of this paper to provide physiotherapy schemas, this example demonstrates the critical nature of shortening the low abdominal muscles (such as the symphysis and the pubic arch)

Flat-back posture

The term "flat back posture" refers to the presence of a flat back lordosis and a flat kyphosis, with or without dorsal kyphosis. Additionally, the upper thoracic region and cervical junction are frequently hypertrophied. The pelvis is maintained in its neutral position.

The upper and lower shoulders frequently overlap in the baseline posture, and the lumbar vertebrae flex (as they did in the old style). The head is located in front of the base (Table 5).

Table 5

The position of body parts in the flat-back posture

Part of the body	Position
Head	Neutral or protracted (moved forward)
Cervical spine	Upper part: extended (hyperlordosis) Lower part: flexed (hypolordosis or kyphosis)
Thoracic spine	Upper part: increased flexion (hyperkyphosis) Lower part: straight (hypokyphosis)
Lumbar spine	Flexed (hypolordosis)
Pelvis	Neutral or decreased anterior tilt
Hip joints	Neutral or extended when decreased anterior tilt of pelvis occurs

Functional state of muscles in the flat-back posture

The erector spinae (lumbar part), one-joint hip flexors (iliacus, psoas), and two-joint hip flexors are typically lengthened in this posture (rectus femoris, tensor fasciae latae). Typically, the iliacus is inactive, whereas the psoas is hyperactive. Hip flexors with two joints are hyperactive.

The gluteus maximus is contracted and hypoactive; the hamstrings are also contracted but hyperactive (Table 6).

Table 6

Functional characteristics of muscles in the flat-back posture

Muscle	Lengthened	Shortened	Hypoactive	Hyperactive
Erector spinae part thoracic (upper part)	+			+
Erector spinae (lumbar part)	+		+	
Iliacus	+		+	
Psoas	+			+
Two-joint hip flexors	+			+
Suboccipital		+		+
Sternocleidomastoid		+		+

Scaleni		+		+
Erector spinae part thoracic (lower part)		+		+
Gluteus maximus		+	+	
Hamstrings		+		

Note: the symbol “+” means that the muscle meets a certain criteria

Sway-back posture

The following characteristics characterize the sway-back posture: (1) anterior pelvic shift, (2) thoracic kyphosis that extends into the upper lumbar spine (a longer thoracic kyphosis is observed), (3) shorter lumbar lordosis, and (4) normal or slightly decreased anterior pelvic tilt.

The pelvis is in front of the headline in the sway-back position, while the upper part of the trunk is typically shifted posteriorly to this axis. Typically, the headline and baseline overlap, indicating the head's normal position. On the other hand, the head is elongated as a result of the chest position about the base and the headline. The headline passes posteriorly to the lumbar vertebral bodies (causing them to be overextended) and posteriorly to the axis of the hip joints (leading to an overload of the hip joints).

Table 7

The position of body parts in the sway-back posture

Part of the body	Position
Head	Protracted (moved forward)
Cervical spine	Upper part: extended (hyperlordosis) Lower part: flexed (hypolordosis or kyphosis)
Thoracic spine	Upper part: increased flexion (hyperkyphosis) Lower part: normal (kyphosis)
Lumbar spine	Upper part: flexion (kyphosis or hypolordosis) Lower part: increased extension (hyperlordosis)
Pelvis	Shifted anteriorly, decreased anterior tilt
Hip joints	Extended due to decreased anterior tilt of pelvis

Functional state of muscles in the sway-back posture

The erector spinae in the upper thoracic and upper lumbar regions, the muscles that stabilize the scapula (serratus anterior, lower and middle trapezius, and rhomboid muscles), abdominal muscles (their lower segment), and one- and two-joint hip flexors (iliacus, psoas) are lengthened.

Suboccipital, sternocleidomastoid, and scalene muscles are shortened, as are the chest muscles pectoralis major and minor, Erector spinae lumbar part (lower part), upper abdominal muscle fibers, gluteus maximus, and hamstrings. These muscles are hyperactive (except the lower lumbar erector spinae, the posterior oblique abdominal muscle, and the gluteus maximus) (Table 8).

Table 8

Functional characteristics of muscles in the sway-back posture

Muscle	Lengthened	Shortened	Hypoactive	Hyperactive
Trapezius (middle and lower part)	+		+	
Serratus anterior	+		+	
Rhomboideus major and minor	+		+	
Erector spinae part thoracic (upper part)	+			+
Erector spinae lumbar part (upper part)	+		+	
Rectus abdominis (lower fibers)	+			+
Abdominal internal oblique (anterior part, lower fibers)	+			+
Abdominal internal oblique (posterior part, lower fibers)	+		+	
Abdominal external oblique (lower fibers)	+			+
Iliacus	+		+	
Psoas	+			+
Two-joint hip flexors	+			+
Suboccipital		+		+
Sternocleidomastoid		+		+
Scaleni		+		+
Trapezius (superior part)		+		+
Pectoralis minor and major		+		+
Erector spinae lumbar part (lower part)		+	+	
Rectus abdominis (upper fibers)		+		+
Abdominal internal oblique (anterior part, upper fibers)		+		+

Abdominal internal oblique (posterior part, upper fibers)		+	+	
Abdominal external oblique (upper fibers)		+		+
Gluteus maximus		+	+	
Hamstrings		+		+

Note: the symbol “+” means that the muscle meets a certain criterion

DISCUSSION:

Its purpose was to describe the three most prevalent forms of sagittal, nonstructure misalignment of human posture: lordosis, kyphosis, and scoliosis. They all can affect the spinal and muscular systems, increasing the risk of back and joint pain. It was written based on the authors' personal experience with posture problems and treatments.

To maintain equilibrium, antagonistic muscles should be strong but flexible, such as the anterior and brachial plexus ocular muscles.

Kendall et al. state that muscles can be evaluated for their length and strength. That is why the abs, gluteus maximus, and posterior hamstrings are lengthened. The erector spinae, quadratus lumborum, and hip flexors, on the other hand, are shortened. It was suggested that excessively long muscles are typically weak, whereas those that are excessively short are typically antagonistic. According to our experience, muscle length and strength are considered when prescribing corrective exercises. A clinically important question remains: do muscle lengthening tests correlate with the Kendall et al. classifications? It was established in the paper through the use of muscle classification. Muscle tension may be accompanied by hamstring lengthening.

According to Kendall et al., a boy's pelvic tilt can be lengthened if it is posterior. These muscles should be strengthened during corrective exercises. The prolonged sitting and popliteal test, on the other hand, reveal pertinent information for a more expansive range of motion (the popliteal angle test). The test results indicate decreased adaptability. As a result, the only logical course of action is to stretch the hamstrings. The tests indicated that the hams had shrunk in length. Regrettably, the literature indicates that the lordotic muscles should be lengthened in this posture. This can be answered using the muscle classification proposed by Bergmark and colleagues,

who believe that muscle weakness is unlikely to be caused by either hyperactivity or hypoactivity. Postural strengthening should not focus on the hamstrings but rather on the normal balance of the hamstrings and glutes (according to Kendall et al.). (as determined by the results of functional tests). In this case, the exercises should be directed toward reestablishing the gluteus Maximus's function. Additionally, the exercises should be performed within the confines of what is known as the internal (short) range of motion.

As a result, it is critical to verify muscle length and function (hyper- or hypoactivity). Additionally, when a person spends the majority of the day in one of those positions, it is critical to choose exercises based on the individual posture analysis; each position should be evaluated about one of the four previously mentioned poses, not all of them (e.g., sitting, position at work or while learning, position during learning or hobby).

In breast cancers, Our findings demonstrate that postural changes can be detected even following total mastectomy and the use of external breast prostheses or tissue expanders. BG patients demonstrated a greater restriction in sagittal spine alignment for anterior–posterior trunk flexion and lumbosacral inversion point than CG patients, as well as a significant pelvic inclination and twist of half-pelvis, as well as an increase in surface rotation and lateral deviation. Additionally, in breast cancer patients, postural control requires a greater energy expenditure due to the increasing length and area of the ellipse used for stabilometry evaluation.

Another study discovered that immediate breast reconstruction significantly reduced the amount of change in spinal alignment in postoperative breast cancer patients compared to patients who received only unilateral mastectomy without reconstruction; thus, immediate breast reconstruction improves spinal

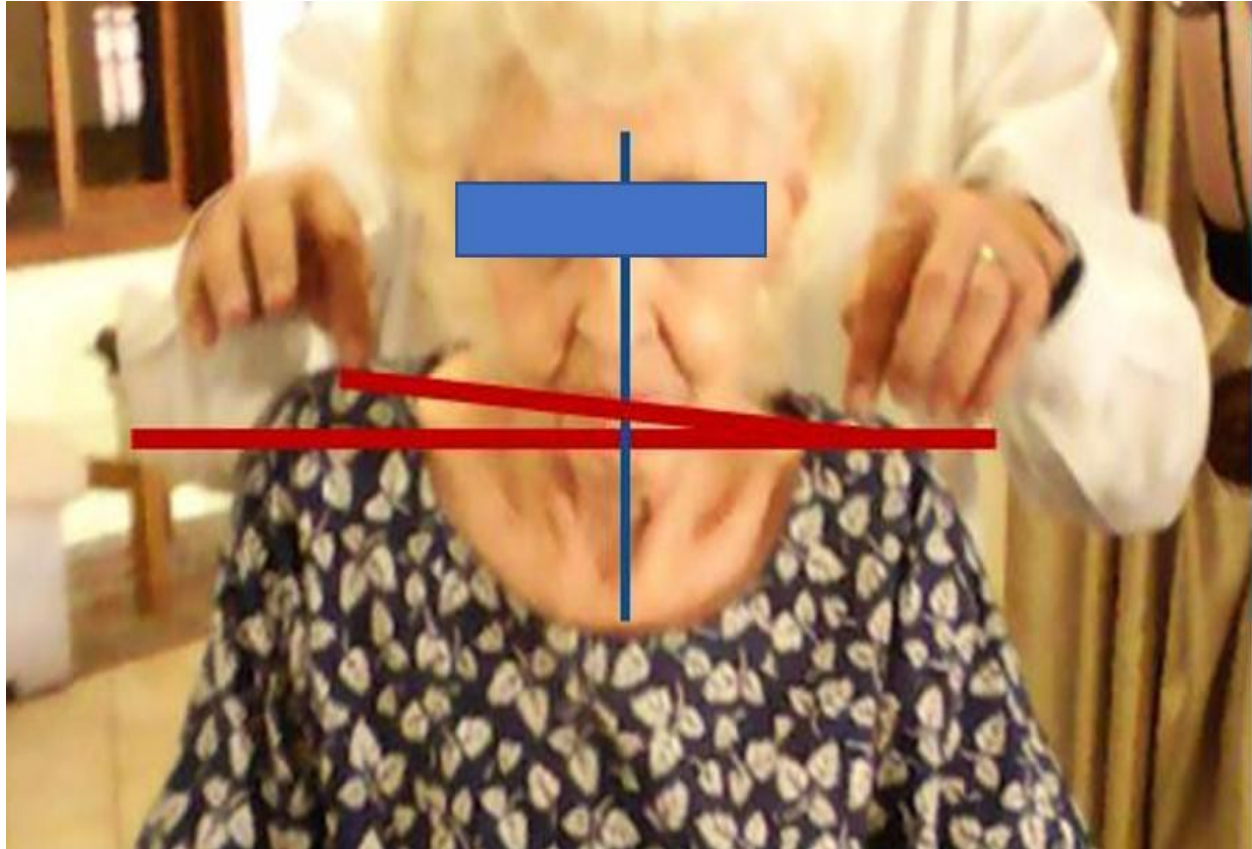
alignment, resulting in improved posture and physical function.

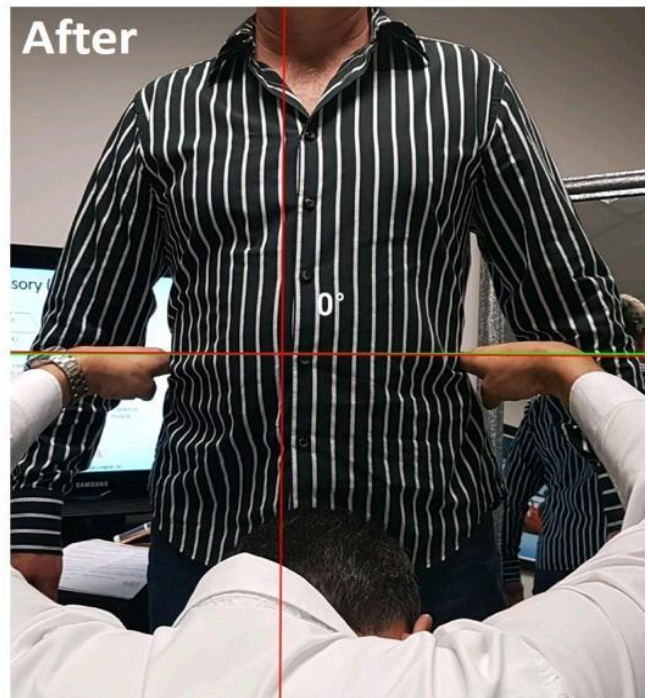
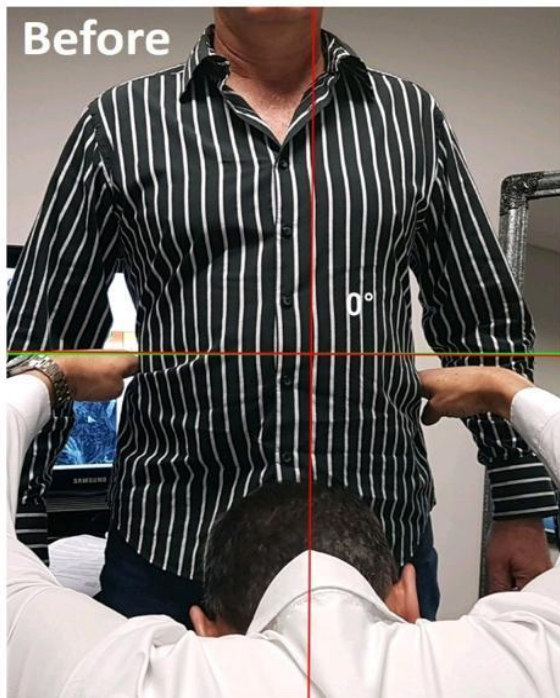
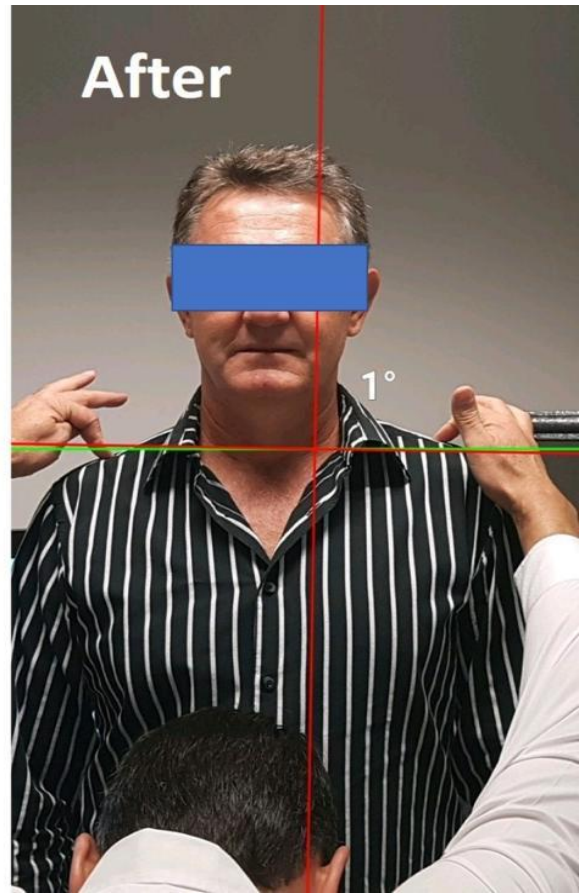
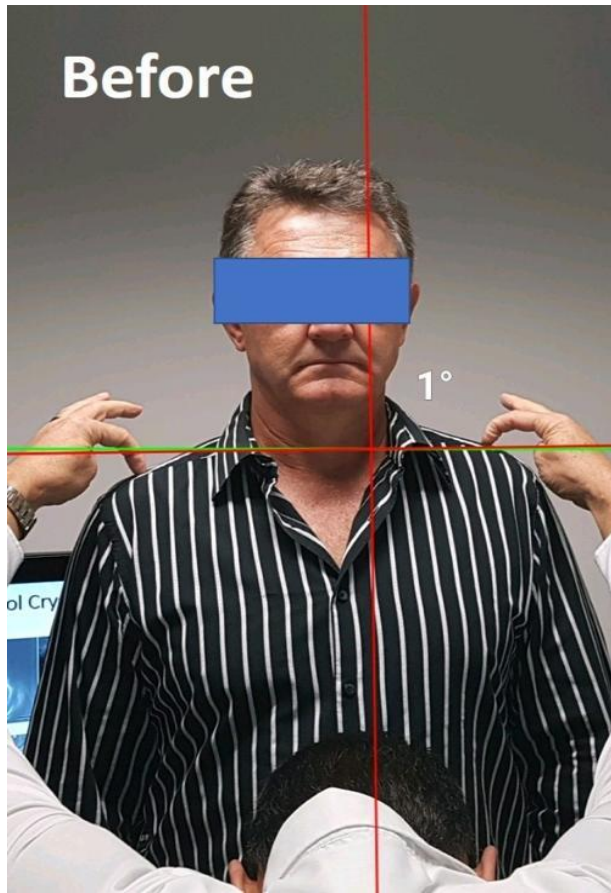
Almost all cancer patients experience spinal misalignment, some preoperatively and others postoperatively, as is the case with breast cancer.


Cell Quicken Focused Ultrasound For spine alignment

A chiropractor will adjust the spine's alignment. The spine is misaligned as a result of tense or spasming

muscles. Thus, the muscle must release in order for the spine to align, the muscle is controlled by the nervous system, and thus the nervous system must be addressed in order for the muscle to release the tension, and thus chiropractor visits can be reduced or eliminated when the nervous system is treated and the spine is aligned. The spine alignment can be performed at home with or without the assistance of a family member.







Therapy Balls

By treating the nerves that control the muscles and aligning the spine with the therapy balls, the need for chiropractic visits is eliminated, and this therapy can be performed daily if necessary. Among the benefits are relief from ADHD, headaches, hip and knee pain, and forward head syndrome.

CONCLUSION:

In the sagittal plane, there are four non-structural body postures: Kyphotic, Lumbago, Flatback, and Sway-back. When the musculoskeletal system is overloaded, functional disorders can result.

When evaluating muscle length or strength, it is necessary to consider the function of the muscle in maintaining proper posture.

Corrective exercises for alignment should begin with a thorough clinical assessment, and subsequent corrective exercises should be directed toward that goal.

REFERENCES:

1. Raymond L Venter., Environmental Energy for Cellular Growth And Repair Especially By Bio-

- Resonance Focused Ultrasound: A Literature Review., *Indo Am. J. P. Sci.*, 2021; 08(04).
2. Raymond L Venter., Role Of Bio-Resonance Focused Ultrasound On Stem Cell Proliferation And Growth: A Review., *Indo Am. J. P. Sci.*, 2021; 08(04).
 3. Irene H James., Cellular Destruction From Environmental Energy Exposure Especially By Cell Phones And Mobile Internet., *Indo Am. J. P. Sci.*, 2021; 08(04).
 4. Raymond L Venter., Focused Ultrasound Involving The Usage Of Cell Resonance To Understand The Effect And Its Use As A Therapy For Disease Modification., *Indo Am. J. P. Sci.*, 2021; 08(03).
 5. James, D. I. H. (2021, May). RECORDING AND INTERPRETATION OF CELLULAR BIO-RESONANCE FOR THE IDENTIFICATION OF CELLULAR HEALTH STATUS: A DIAGNOSTIC AND THERAPEUTICS LITERATURE REVIEW. *WORLD JOURNAL OF PHARMACEUTICAL AND MEDICAL RESEARCH*, 7(5), 303-309. https://www.wjpmr.com/home/article_abstract/3505
 6. Venter, D. R. L. (2021, May). ROLE OF BIO-RESONANCE FOCUSED ULTRASOUND ON STEM CELL PROLIFERATION AND GROWTH: A REVIEW. *WORLD JOURNAL OF PHARMACEUTICAL AND MEDICAL RESEARCH*, 7(5), 310-315. https://www.wjpmr.com/home/article_abstract/3506
 7. Claus A, Hides JA, Moseley GL, Hodges PW. Different ways to balance the spine: subtle changes in sagittal spinal curves affect regional muscle activity. *Spine*. 2009;34(6):208–214. doi: 10.1097/BRS.0b013e3181908ead.
 8. O’Sullivan PB, Grahamslaw KM, Kendell M, et al. The effect of different standing and sitting postures on trunk muscle activity in a pain-free population. *Spine (Phila Pa 1976)* 2002;27:1238–1244. doi: 10.1097/00007632-200206010-00019.
 9. Kendall F, McCreary E, Provance PG, Rodgers M, Romani WA. *Muscle testing and function with posture and pain*. Baltimore: Lippincott Williams & Wilkins; 2005.
 10. Janssen MM, Kouwenhoven JW, Schlösser TP, Viergever MA, Bartels LW, Castelein RM, Vincken KL. Analysis of preexistent vertebral rotation in the normal infantile, juvenile, and adolescent spine. *Spine (Phila Pa 1976)* 2011;36(7):486–491. doi: 10.1097/BRS.0b013e3181f468cc.
 11. Levangie PK, Norkin CC. *Joint structure and function: a comprehensive analysis*. F.A. Davis Company, 2005.
 12. McGill S. *Low Back Disorders-3rd Edition with Web Resource: Evidence-Based Prevention and Rehabilitation*. Human Kinetics; 3 edition, Champaign, USA; 2015.
 13. Sahrmann S. *Diagnosis and treatment of movement impairment syndromes*. St. Louis: Mosby; 2002.
 14. Comerford M, Mottram S. *Kinetic control—e-book: the management of uncontrolled movement*. 2012.
 15. Bergmark A. Stability of the lumbar spine. A study in the mechanical engineering. *Acta Orthop Scand Suppl.* 1989;230:20–24.
 16. Richardson CA, Hodges PW, Hides J. *Therapeutic exercise for lumbopelvic stabilization: a motor control approach for the treatment and prevention of low back pain*. 2. Edinburgh: Churchill Livingstone; 2004.
 17. Richardson C. The muscle designation debate: the experts respond. *J Bodyw Mov Ther.* 2000;4(4):235–236.
 18. Richardson C, Bullock MI. Changes in muscle activity during fast alternating flexion-extension movements of the knee. *Scand J of Rehabil Med.* 1986;18:51–58.
 19. Appell HJ. Muscular atrophy following immobilization: a review. *Sports Med.* 1990;10:42. doi: 10.2165/00007256-199010010-00005.
 20. Hides JA, Stokes MJ, Saide M, Jull GA, Cooper DH. Evidence of lumbar multifidus muscle wasting ipsilateral to symptoms in patients with acute/subacute low back pain. *Spine.* 1994;19:165–172. doi: 10.1097/00007632-199401001-00009.
 21. Dilani Mendis M, Hides JA, Wilson SJ, Grimaldi A, Belavý DL, Stanton W, Felsenberg D, Rittweger J, Richardson C. Effect of prolonged bed rest on the anterior hip muscles. *Gait Posture.* 2009;30(4):533–537. doi: 10.1016/j.gaitpost.2009.08.002.
 22. Hides JA, Belavý DL, Stanton W, Wilson SJ, Rittweger J, Felsenberg D, Richardson CA. Magnetic resonance imaging assessment of trunk muscles during prolonged bed rest. *Spine (Phila Pa 1976)* 2007;32(15):1687–1692. doi: 10.1097/BRS.0b013e318074c386.
 23. Hides JA, Lambrecht G, Stanton WR, Damann V. Changes in multifidus and abdominal muscle size in response to microgravity: possible implications for low back pain research. *Eur Spine J.*

- 2016;25(Suppl 1):175–182. doi: 10.1007/s00586-015-4311-5.
24. Hides JA, Belavý DL, Cassar L, Williams M, Wilson SJ, Richardson CA. Altered response of the anterolateral abdominal muscles to simulated weight-bearing in subjects with low back pain. *Eur Spine J*. 2009;18(3):410–418. doi: 10.1007/s00586-008-0827-2.
 25. Reeve A, Dilley A. Effects of posture on the thickness of transversus abdominis in pain-free subjects. *Man Ther*. 2009;14(6):679–684. doi: 10.1016/j.math.2009.02.008.
 26. Bogduk N, Twomey LT. *Clinical anatomy of the lumbar spine*. 2. London: Churchill Livingstone; 1991.
 27. Hides JA, Lambrecht G, Richardson CA, Stanton WR, Armbrrecht G, Pruett C, Damann V, Felsenberg D, Belavý DL. The effects of rehabilitation on the muscles of the trunk following prolonged bed rest. *Eur Spine J*. 2011;20(5):808–818. doi: 10.1007/s00586-010-1491-x.
 28. Belavý DL, Richardson CA, Wilson SJ, Rittweger J, Felsenberg D. Superficial lumbopelvic muscle overactivity and decreased cocontraction after 8 weeks of bed rest. *Spine (Phila Pa 1976)* 2007;32(1):232–239. doi: 10.1097/01.brs.0000250170.53746.27.
 29. Lee DG. *The Pelvic Girdle: An integration of clinical expertise and research*. Churchill Livingstone; 4 edition USA; 2010.
 30. Bullock-Saxton J, Murphy D, Norris C, Richardson C, Tunnel P. The muscle designation debate: the experts respond. *J Bodyw Mov Ther*. 2000;4(4):225–257. doi: 10.1054/jbmt.2000.0180.
 31. Kędra A, Czaprowski D. Sedentary behaviours of 10-19-year-old students with and without spinal pain. *Probl Hig Epidemiol*. 2015;1(96):143–148.
 32. Czaprowski D, Stoliński Ł, Szczygieł A, Kędra A. Sedentary behaviours of girls and boys aged 7-15. *Polish Journal of Public Health*. 2011;121(3):248–252.
 33. Solberg G. *Postural disorders & musculoskeletal dysfunction. Diagnosis, prevention and treatment*. Philadelphia: Elsevier Churchill Livingstone; 2008.
 34. Gajdosik RL, Albert CR, Mitman JJ. Influence of hamstring length on the standing position and flexion range of motion of the pelvic angle, lumbar angle, and thoracic angle. *J Orthop Sports Phys Ther*. 1994;20(4):213–219. doi: 10.2519/jospt.1994.20.4.213.
 35. Fujitani R, Jiomaru T, Kida N, Nomura T. Effect of standing postural deviations on trunk and hip muscle activity. *J Phys Ther Sci*. 2017;29(7):1212–1215. doi: 10.1589/jpts.29.1212.
 36. Crosible J, Kilbreath SL, Hollman L, et al. . Scapulohumeral rhythm and associated spinal motion. *Clin Biomech*. 2008;23:184–192
 37. Crosible J, Kilbreath SL, Dylke E, et al. . Effect of mastectomy on shoulder and spinal kinematics during bilateral upper-limb movement. *Physical*. 2010;90:679–692
 38. Yamamoto D, Tanaka Y, Tsubota Y, et al. . Immediate breast reconstruction for breast cancer. *Gan To Kagaku Ryoho*. 2014;41:1892–1894
 39. Fischer JP, Fox JP, Nelson JA, et al. . A longitudinal assessment of outcomes and healthcare resource utilization after immediate breast reconstruction-comparing implant- and autologous-based breast reconstruction. *Ann Surg*. 2015;262:692–699.
 40. Atanes Mendes Peres AC, Dias de Oliveira Latorre MD, Yugo Maesaka J, et al. . Body posture after mastectomy: comparison between immediate breast reconstruction versus mastectomy alone. *Physiother Res Int*. 2017;22:1
 41. Mazzocchi M, Dessy LA, Di Ronza S, et al. . A study of postural changes after breast reduction. *Aesthetic Plast Surg*. 2012;36:1311–1319
 42. Mazzocchi M, Dessy LA, Iodice P, et al. . A study of postural changes after breast augmentation. *Aesthetic Plast Surg*. 2012;36:570–577